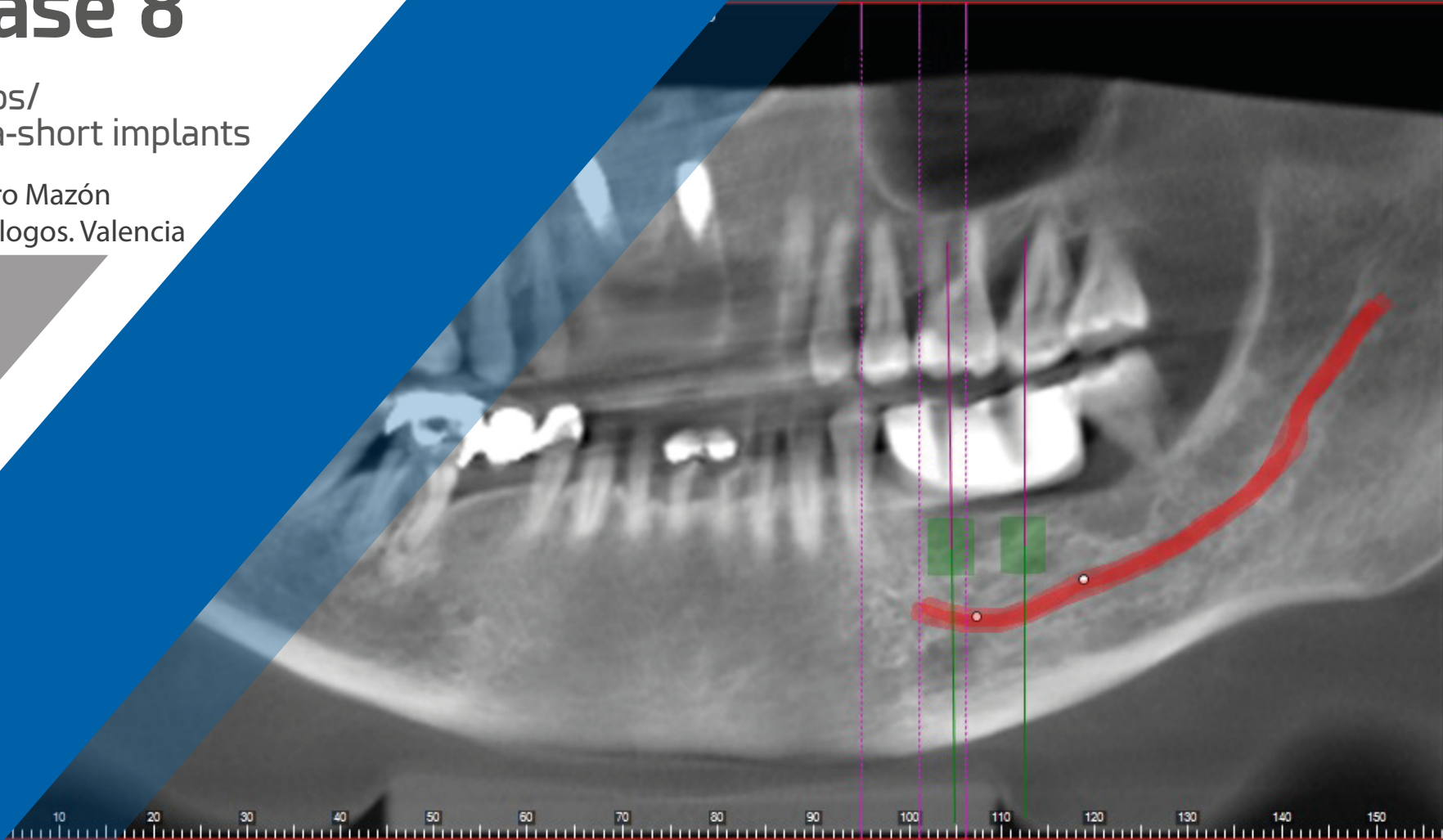


Caso clínico 8 / Clinic Case 8

Control Radiográfico
implantes extra-cortos/
X-ray control of extra-short implants

Colaboración Dr. Juan Pedro Mazón
Esteve. Cliniksalud Odontólogos. Valencia

ZIACOM®

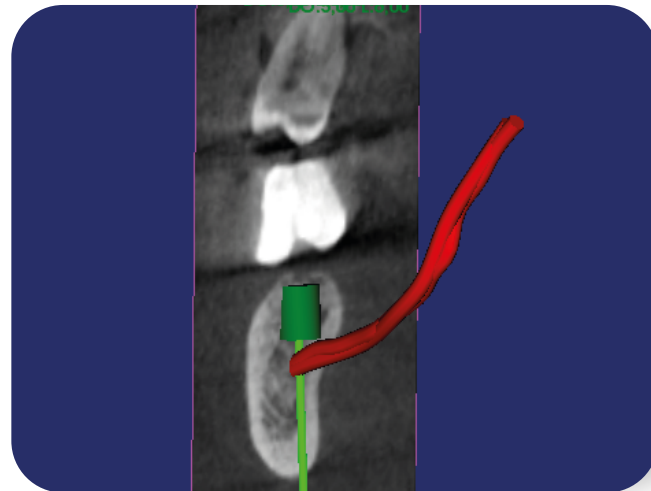
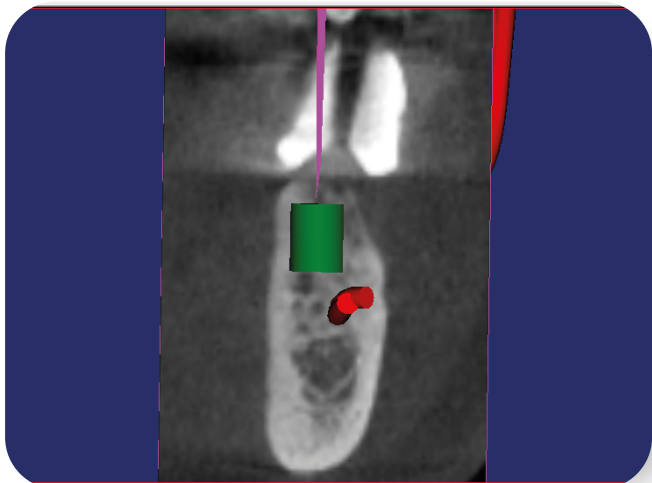
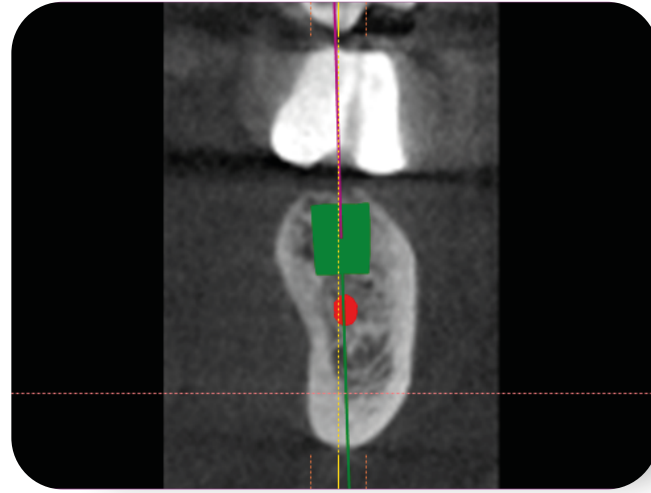
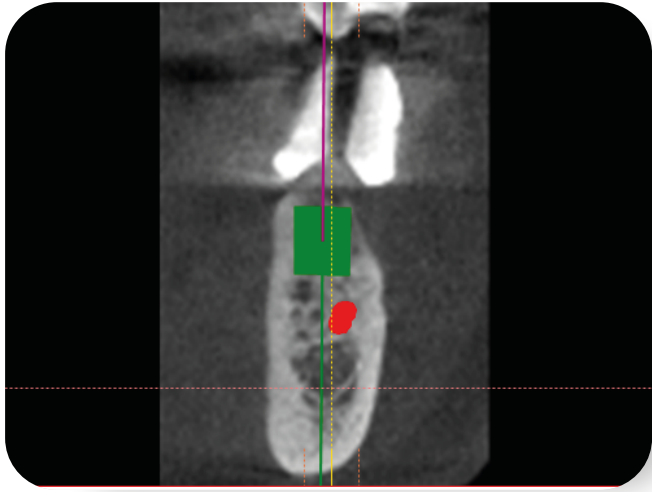


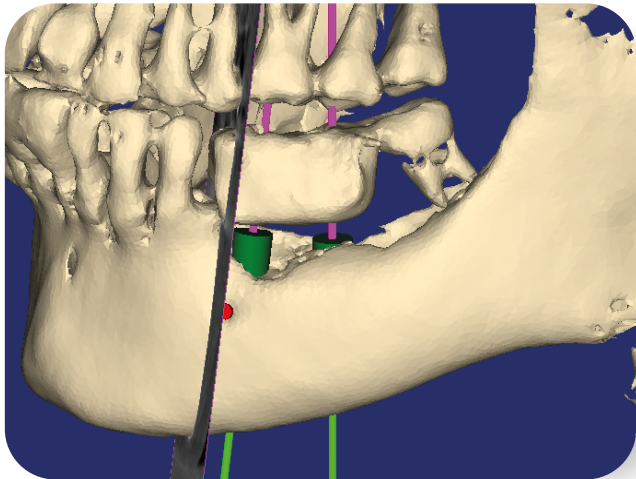
- Género: Femenino
- Edad: 59 años
- Tratamiento: Colocación de Implantes extra cortos
- Tipo y talla de implante: OST®
- 36 y 37 ø 5,25*6,5mm

- Gender: Female
- Age: 59 years old
- Treatment: extra-short implants
- Type and Implan size: OST®
- 36 y 37 ø 5,25*6,5mm

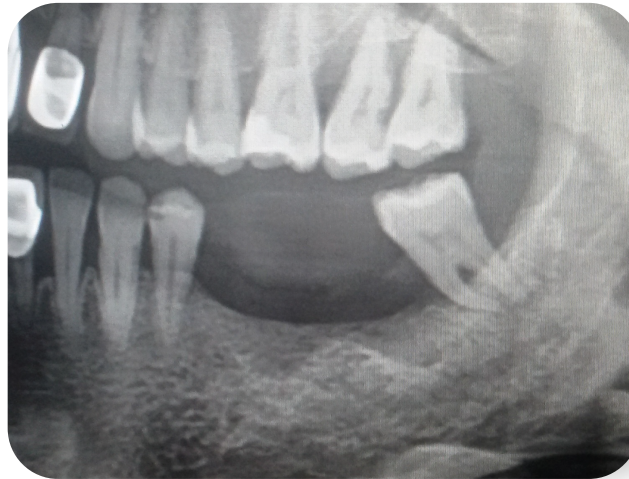


OST®

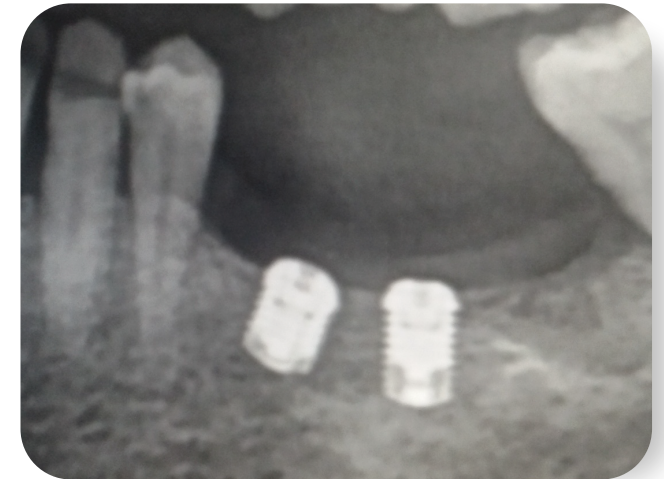



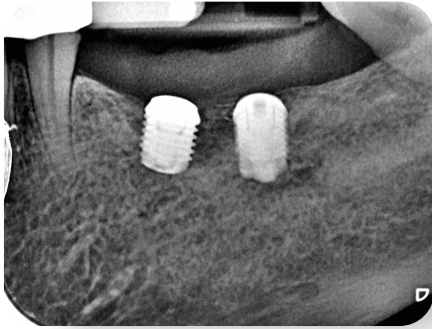
RECONSTRUCCIÓN 3D
/ 3D RECONSTRUCTION



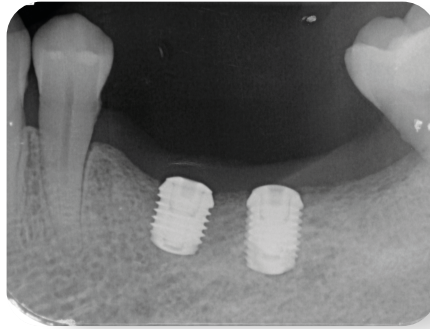
RX INICIAL 27/11/2014
/ INITIAL X-RAY 27/11/2014



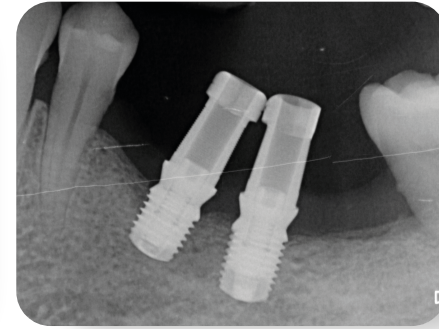
RX POSTQUIRÚRGICA 15/01/2015 /
POST SURGICAL X-RAY 15/01/2015



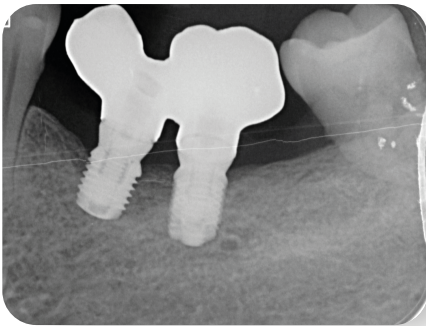
RX CONTROL A LOS 7 DIAS
(22/01/2015) / X-RAY CONTROL
7 DAYS (22/01/2015)



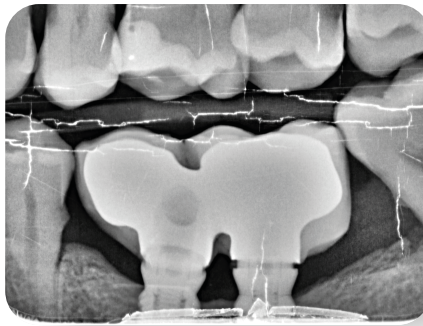
RX CONTROL A LOS
2 MESES (12/03/2015) /
X-RAY CONTROL 2
MONTHS (12/03/2015)



RX CON TRANSFER DE
IMPRESIÓN
(3 MESES) (9/04/2015) /
X-RAY WITH
IMPRESSION TRANSFER
(3 MONTHS) (9/04/2015)



RX CONTROL PRÓTESIS
(4 MESES) 7/05/2015 /
PROSTHESIS CONTROL
X-RAY
(4 MONTH) 07/05/2015



RX CONTROL
(2 AÑOS) 16/03/2017 /
X-RAY CONTROL
(2 YEARS) 16/03/2017

