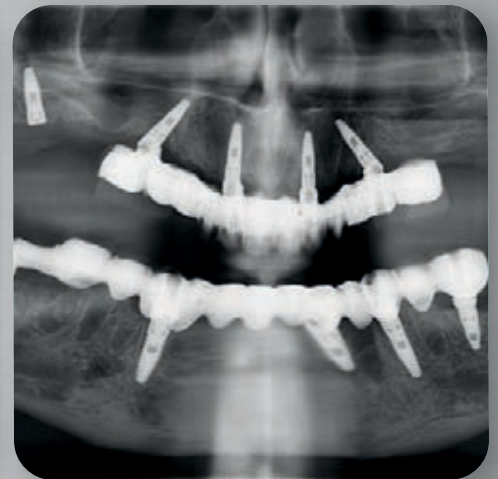
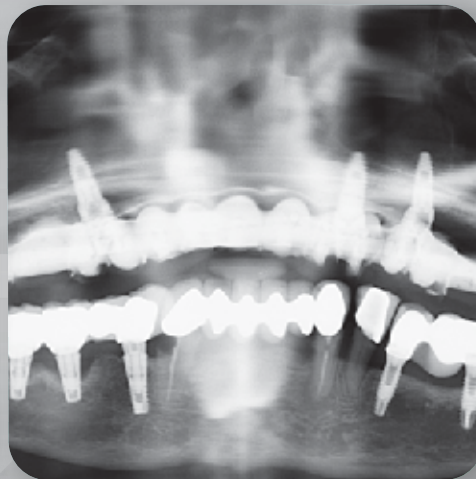
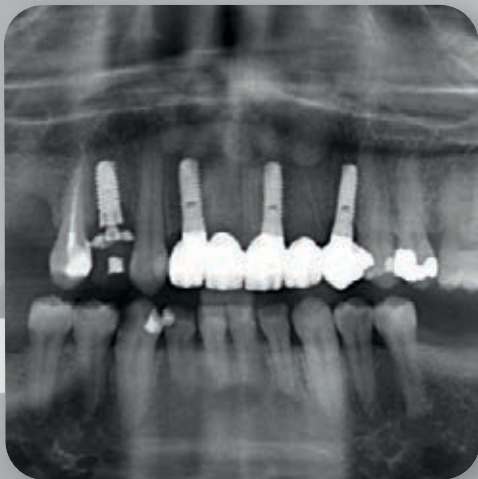

Clinical cases  
Magazine publications  
Volume 1







Clinical cases

Magazine publications

Volume 1



Sede Central Europa | Europe Headquarters  
**Ziacom Medical SLU**  
Calle Búhos, 2  
28320 Pinto - Madrid - ESPAÑA  
Tfno: +34 91 723 33 06  
[info@ziacom.es](mailto:info@ziacom.es) - [www.ziacom.es](http://www.ziacom.es)

Sede Central América | America Headquarters  
**Ziacom Medical USA LLC**  
333 S.E. 2nd Avenue, Suite 2000  
Miami, FL 33131 - USA  
Tel: +1 (786) 224 - 0089  
[info.usa@ziacom.es](mailto:info.usa@ziacom.es) - [www.ziacom.es](http://www.ziacom.es)



## Important information

### Read this carefully before using ZIACOM® products

#### General information

This document contains basic information about the use of ZIACOM® Dental Implant Systems, henceforth, ZIACOM® products. This document has been written as a quick reference guide for the professional in charge of the treatment, henceforth, "User". It does not provide sufficient indications and technical specifications for the use of ZIACOM® products. It is neither an alternative nor a substitute for specialised training and professional clinical experience.

ZIACOM® products must be used in accordance with proper treatment planning and in strict accordance with the surgical and prosthetic protocols established by the manufacturer. Before using a ZIACOM® product, please read the specific surgical and prosthetic protocols as well as the operating and maintenance instructions carefully. You can consult them on our website [www.ziacom.es](http://www.ziacom.es) or request them from your nearest ZIACOM® authorised distributor.

#### Information about responsibility, safety and guarantee.

The indications for use and handling of ZIACOM® products are based on the published international literature, current clinical standards and our clinical experience with our products and should therefore be understood as general indicative information. The handling and use of ZIACOM® products, as they are beyond the control of Ziacom Medical SLU, are the sole responsibility of the user. Ziacom Medical SLU, its subsidiaries and/or its official distributors decline all responsibility, express or implicit, totally or partially, for any possible damage or loss caused by the improper handling of the product or by any other fact not contemplated in its protocols and manuals for the correct use of its products.

The user of the product must ensure that the ZIACOM® product used is suitable for the intended procedure and purpose. Neither these instructions for use nor the protocols for working with or handling the products relieve the user of this obligation. The use, handling and clinical application of ZIACOM® products must be carried out by qualified professional personnel with the necessary qualifications according to the current legislation of each country.

The use, handling and/or application, fully or in part, of ZIACOM® products in any of their manufacturing phases by unqualified personnel or without the necessary qualifications, automatically voids any type of guarantee and may cause serious damage to the patient's health.

ZIACOM® products are part of an own system, with its design features and working protocols, which include dental implants, abutments and prosthetic components and surgical or prosthetic instruments. The use of ZIACOM® products in combination with elements or components from other manufacturers can lead to treatment failure, serious damage to bone structures, tissue and patient health, as well as undesired cosmetic results. For this reason, only original ZIACOM® products should be used.

The clinician, who is responsible for the treatment, is solely responsible for ensuring that original ZIACOM® products are used and that they are used in accordance with the instructions for use and the corresponding handling protocols throughout the entire implant treatment process. The use of ZIACOM® components, instruments or any other non-original product used alone or in combination with any of the original ZIACOM® products will automatically void any guarantee on the original ZIACOM® products.

Please consult the ZIACOM® Guarantee Program on our website [www.ziacom.es](http://www.ziacom.es)

**Warning.** Non entire ZIACOM® products are available in all countries. Please consult their availability.

ZIACOM®, Zinic®, Zinic®MT, Zinic®Shorty, OEX®, OEX®MT, OEX®ST, OIN®, OIN®MT, OIN®ST, OXP®, ZMK®, ZMR®, OST®, ZM1®, ZM1®MT, ZM4®, ZM4®MT, ZM8®, ZM8®N, ZM8®S, Galaxy®, ZV2®, Zinic®3D, TPlus®, XPlus®, ZPlus®, Z2Plus®, 3DPlus®, Kiran®, Kirator®, ZM-Equator®, Basic®, XDrive®, ZiaCam®, ZIACOR®, Tx30®, Zellplex®, ZellBone®, PlexGuide®, OsseosBCP®, OsseosTCP®, Osseolife®, Osseonova® and all logos are trademarks of Ziacom Medical SLU.

The brand ZIACOM® is a registered trademark as some of its products mentioned or not in this catalogue. Ziacom Medical SLU reserves the right to modify, change and remove any of the products, prices or technical specifications which are referenced in this document or in any of its catalogues without prior notice. All rights reserved. It is strictly forbidden the reproduction or publication of this document, in whole or in part, in any form or by any means, without prior written permission of Ziacom Medical SLU.



## Index

Implant Dentistry	4
Maxillaris	24
Dentistry case 1	36
Maxillaris Anuario 2018	42
Dentistry case 2	46
Dentistry case 3	48
Maxillaris Anuario 2017	52
Dentista Moderno	56
Gaceta Dental	58
Avances en periodoncia e implantología oral	70



*applied  
sciences*

Date: 13 July 2020

Article name: Influence of Three Dental Implant Surfaces on Cell Viability and Bone Behavior. An In Vitro and a Histometric Study in a Rabbit Model

Products: Zinic®

Dentist: Dr. Daniel Torres

Article

# Influence of Three Dental Implant Surfaces on Cell Viability and Bone Behavior. An In Vitro and a Histometric Study in a Rabbit Model

María Rizo-Gorrita, Ignacio Fernandez-Asian, Andreina Garcia-de-Frenza, Celia Vazquez-Pachon, Maria-Angeles Serrera-Figallo \*, Daniel Torres-Lagares  and Jose-Luis Gutierrez-Perez

Department of Oral Surgery, College of Dentistry, Seville University, Calle de Avicena s/n 41009 Seville, Spain; marrizgor@alum.us.es (M.R.-G.); ifernasi@gmail.com (I.F.-A.); andruxgarciax90@hotmail.com (A.G.-d.-F.); celiavazpac@gmail.com (C.V.-P.); danieltl@us.es (D.T.-L.); jlgp@us.es (J.-L.G.-P.)

\* Correspondence: maserrera@us.es

Received: 3 June 2020; Accepted: 8 July 2020; Published: 13 July 2020



**Abstract:** The chemical composition and the surface characteristics of dental implants are factors that have a decisive effect on the osseointegration process. The surface characterization at the compositional and topographic level of three dental implants available in the market was performed with different surface treatments: (1) sandblasted and acid etched surface (SLA), (2) hydroxyapatite (HA) and tricalcium phosphate (TCP) blasted surface (HA/TCP), and (3) HA-blasted and non-etching acid washed surface (HA + AW). In addition, an in vitro viability study of MG-63 osteoblast cells was performed with a JC-1 test. To complete the study, an in vivo study was conducted in New Zealand rabbits. The study analyzed the histometric characteristics of the bone formed around the implants at the level of area, volume, bone density, accumulated bone density, and bone–implant contact (BIC). The rabbits were sacrificed at 6 weeks after implants were placed in the tibial metaphysis. No statistically significant differences were observed at the level of cell viability or histometric parameters between the different study groups ( $p > 0.05$ ). SLA and HA/TCP surfaces were the ones that obtained a higher BIC value. Taking into account the limitations of this study, it can be concluded that the different implant surfaces analyzed favor a good bone response.

**Keywords:** dental implant surfaces; surface roughness; titanium; osseointegration; bone–implant interface

## 1. Introduction

Since titanium (pure or in alloys) began to be used as a dental implant material in the 1960s, the goal has been to improve the design and surface of the different implants available on the market, as well as to develop new implants that improve osseointegration behavior, aimed at shortening healing times or, for example, improving primary stability in the face of low-density bone.

Grade IV (commercially pure) or alloy titanium implants are used currently, with the Ti6Al4V alloy being the most widely used one [1]. Pure titanium has high strength, while type V, thanks to the presence of elements such as vanadium or aluminum, has high resistance to corrosion, fracture, and fatigue [2–4]. On the other hand, titanium alloys have better mechanical properties than pure titanium [5].

When machined surfaces have been compared with implants with surface treatment, it has been observed that the latter improve osseointegration by increasing bone–implant contact and therefore long-term survival rate. This is partly due to the chemical composition of the implant and also to its topographical characteristics [6].

The main surface treatment methods are sandblasting, acid etching (there may be a combination of the latter two techniques, which is called SLA), or anodic oxidation. [7].

Sandblasting is based on the use of particles to modify the surface of the implant. These are generally medium grain particles (250–500 µm). The aim is to create surface macro-roughness [8]. Particles of alumina, titanium oxide, and corundum are usually used [9].

In recent years, the technique of sandblasting with resorbable bioceramic particles such as hydroxyapatite, calcium phosphate, or tricalcium phosphate has been developed. They all replace the use of alumina as a sanding material to prevent these particles from interfering with the subsequent osseointegration of the implant [10].

On the other hand, double acid etching is based on the immersion of the implant for several minutes in a mixture of acids, such as hydrofluoric acid with nitric acid or sulphuric acid with hydrochloric acid [11]. It intends to create micro-roughness with a topography based on craters and microwells on the surface of the implant [8,12]. This procedure allows not only to increase the roughness, but also to remove surface contaminating particles derived from sandblasting or its manufacture, as they may interfere (sometimes with a negative effect) with the osteoconductivity of titanium, regardless of its proven biocompatibility [9]. Furthermore, it is also possible to create homogeneous micro-roughness surfaces.

Other more recent techniques seek to unify several of these techniques, either through sandblasting by combination of different bioceramic particles or through a subsequent acid etching. Although there are approximately 1300 commercially available products with different surface treatments on the market, the literature has not yet described the ideal surface to achieve the objectives mentioned above [13].

This study aims to carry out two in vitro studies. The first one is a surface characterization and the second one is a cell viability assay. Both studies were followed by an in vivo study. The working hypothesis was the suitability of the different surfaces in terms of appropriate biocompatibility and osseointegration, as they represent the surfaces used usually.

## 2. Materials and Methods

### 2.1. Dental Implant Groups

This study evaluates the morphological, roughness, and compositional characteristics of the Osseonova<sup>®</sup> surface of the Zinac Ziacom<sup>®</sup> implant (Ziacom Medical S.L., Madrid, Spain), the surface of the Tapered Screw-Vent Zimmer<sup>®</sup> implant (Zimmer Biomet, Warsaw, IN, USA), and the surface of the Internal Implant RBT BioHorizons<sup>®</sup> implant (BioHorizons Implant Systems, Birmingham, AL, USA) (Table 1).

**Table 1.** Description of the characteristics of the implants analyzed in the study.

Implant Manufacturer	Surface Name	Group Name	Titanium Grade	Reference
Ziacom	SLA (sandblasted and acid etched)	SLA	Ti grade IV	ZSS4011
BioHorizons	RBT (resorbable hydroxyapatite and tricalcium phosphate (HA and TCP) blast texturing)	HA/TCP	Ti-6Al-4V (grade V)	PGR4009
Zimmer	MTX (microtextured, HA blast, and non-etching acid wash)	HA + AW	Ti-6Al-4V (grade V)	TSVT4B8

The Osseonova<sup>®</sup> surface is derived from a treatment based on white corundum sandblasting and double acid etching with hydrofluoric, sulphuric, and phosphoric acid. This technique allows to create a textured surface through subtraction [14]. The Osseonova<sup>®</sup> surface is of the S.L.A. type [15], and it is obtained from sandblasting with white aluminum oxide and acid etching with hydrofluoric, sulphuric, and phosphoric acid. The RBT surface is based on surface sandblasting with resorbable




materials such as hydroxyapatite and tricalcium phosphate. The MTX surface is based on sandblasting with hydroxyapatite particles together with non-etching acid wash of the surface.

The cell viability on the surfaces of the study groups was then evaluated. Finally, the osseointegration of the implants after their placement in an animal model was also studied.

A total of 24 samples were evaluated and eight implants from each group were analyzed. The samples came in sealed containers and were opened with tweezers for analysis in our laboratory.

## 2.2. Surface Characterization

Surface characterization was based on the morphological, compositional, and roughness analysis of the different surfaces. Morphological and compositional data was taken at the coronal third of the implant, just below the microroughness of the collar implant. Roughness measurements were taken at the apical third (Figure 1).



**Figure 1.** Regions of interest of the surface characterization. Morphological and compositional measurements zone (blue rectangle). Roughness analysis zone (green rectangle).

### 2.2.1. Morphological Analysis of the Surface

A scanning electron microscope (FEI TENEO, Thermo Fisher Scientific Inc., Waltham, MA, USA) was used to evaluate the morphology of the coronal third of implant surfaces under the following conditions: 2 kV accelerating voltage, secondary electron (SE) detector and 200 $\times$ , 12,000 $\times$  magnifications.

### 2.2.2. Elemental Analysis of the Surface

Two cervical areas of the implant root surfaces were analyzed by an energy dispersive X-ray spectrometer (Octane Super, Edax-Ametek, Mahwah, NJ, USA) equipped with a silicon drift detector (SDD), attached to the scanning electron microscope. Two areas of 130  $\mu\text{m}^2$  were analyzed per implant as follows: 20 kV accelerating voltage, 1.6 nA (check if it is correct) beam current, 200 s acquisition period, 3000 $\times$  magnification. We made ZAF correction for quantification. Implants were analyzed as received without any treatment on their surfaces. The results of the analysis are expressed as means and standard deviation of percentage mass content (wt.%).

### 2.2.3. Analysis of Surface Roughness

The roughness study was performed using the Sensofar S NEOX confocal-interferometric microscope (Sensofar Medical, Terrasa, Spain). SensoMAP Premium 7.4 was the software used. Measurements were made in accordance with ISO 25178: Geometric Product Specifications (GPS)-Surface texture: areal. A 20 $\times$  epi-illumination lens was used at a focal length of 4.50 mm and a green optical resolution of 0.32  $\mu\text{m}$ . Five measurements were made at the apical third of the implant, with a pre-established area dimension of 0.87  $\times$  0.66  $\text{mm}^2$  and a cut-off correction of 250  $\mu\text{m}$  (Figure 2). The quantitative roughness parameters used were profile mean arithmetic roughness (Ra), mean square deviation of the roughness profile (Rq), maximum peak height of the roughness profile (Rp), maximum valley depth of the roughness profile (Rv) and three-dimensional surface roughness (Sa), three-dimensional root mean square height (Sq), three-dimensional maximum peak height (Sp), three-dimensional maximum pit height (Sv). Mean and standard deviation were expressed in microns ( $\mu\text{m}$ ).



**Figure 2.** Selected zone for roughness measurement at the apical third of the implant.

### 2.3. Cell Viability Study

For the cell viability study on the implant surface, a study of the mitochondrial energy balance of a human MG-63 osteoblastic cell line (Sigma-Aldrich, St. Louis, MI, USA) was performed. This type of cell is a good *in vitro* model, since it maintains its differentiated phenotype throughout progressive subcultures. Cells were cultured in T75 vials until reaching 80% confluence. Implants were placed horizontally inside each T75 culture flask, and cells were cultured on its surface at a density of  $6 \times 10^5$  cells, submerging the implant in the culture medium. Likewise, a control culture was established in Petri dishes at the same cell density. Cell death control was also performed to establish the separation between viable and non-viable cells. Twenty-four hours after culture, each dental implant surface was washed profusely with phosphate-buffered saline (PBS) to recover all attached cells. Pellet was obtained by centrifugation and 500  $\mu\text{L}$  of resuspended medium was analyzed.

Flow cytometry was performed with the MitoProbe™ JC1 kit (Invitrogen, Carlsbad, CA, USA). The JC-1 reagent allowed to evaluate the red/green ratio of mitochondrial activity based on live cells/dead cells. The analysis was performed in the Gallios flow cytometer (Beckman Coulter, Carlsbad, CA, USA). Fluorescence measurements were made at 529 nm (green, diminished membrane potential due to cell damage) and 590 nm (red, intact membrane potential). This test was performed to determine changes in mitochondrial membrane potential during apoptosis processes as the membrane potential is a key indicator of cell health or injury. The results were expressed in mitochondrial activity ratio.

### 2.4. Experimental Animal Study

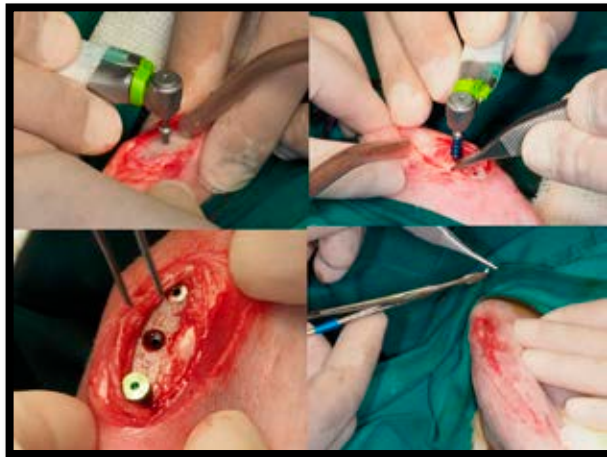
The experimental study was carried out on the tibia of four New Zealand experimental rabbits (age: 6 months; weight: 3.5–4 kg; sex: male). The rabbits were fed rabbit-maintenance Harlan-Teckland Lab Animal Diets (2030).

The animals underwent surgery under general anesthesia at the Jesús Usón Minimally Invasive Surgery Centre (Cáceres, Extremadura, Spain). The experimental study was carried out according to the guidelines of the US National Institute of Health (NIH) and to the European Directive 86/609/EEC, which provides for the care and use of experimental animals for scientific purposes and under all local rules and regulations. Researchers obtained the approval of the Ethics Committee of the Jesús Usón Minimally Invasive Surgery Centre (Cáceres, Extremadura, Spain). As required by the legal framework and due to ethical reasons, the minimum number of animals was used [16]. Comparable models on histological and animal experimental methods have been published [17].

The animals were immobilized, and their vital signs checked. The anesthesia used for initiation was intravenous midazolam (0.25 mg/kg) and propofol (5 mg/kg). By way of maintenance, the animals inhaled 2.8% inspired sevoflurane gas. Analgesia was provided with ketorolac (1.5 mg/kg) and tramadol (3 mg/kg).

After the rabbits were sedated and prepared, a 30 mm long incision was made on the inner side of the tibia with a No. 15 scalpel blade. Epithelial, connective and muscular tissue was displaced using a Prichard periosteal elevator. The surface of the tibia was washed with sterile saline solution while maintaining aspiration.

Three implants (one from each group) were placed in each tibia (six per animal), with 24 implants in total. Implants were selected to be similar, with a diameter of 4 mm and a length of 8–9 mm. Implants were placed 1.5 mm supracrestally, with 8 mm separation between them. The size of the implants was selected based on available implants, always ensuring that their diameter allowed placement within the tibia of the experimental animal (4 mm). The length (8 mm) was selected because it was 1 mm larger than the diameter of the experimental animal's tibia, and this ensured good primary stability. The placement location of the implants in the different study groups in relation to the bone metaphysis was alternated (proximal, middle, or distal locations) so that variations in blood supply and other anatomical characteristics were distributed similarly in all the study groups (Figure 3).



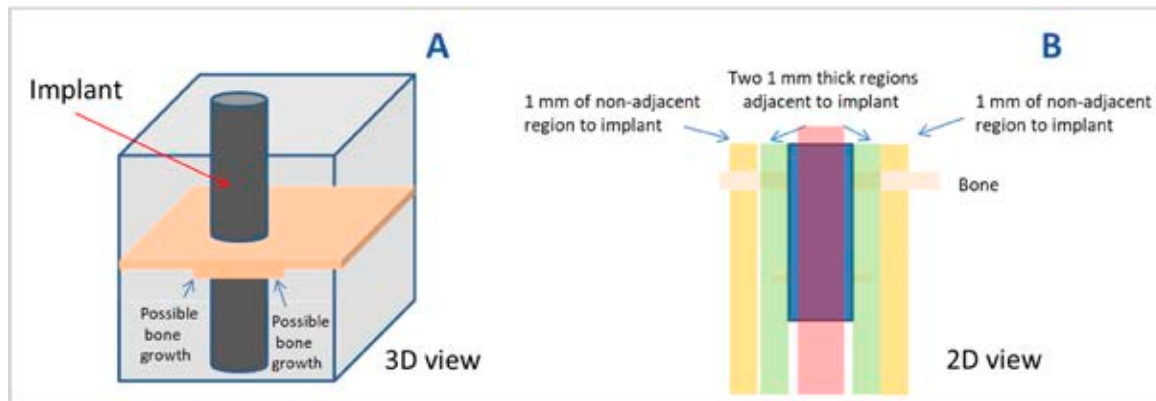
**Figure 3.** Clinical images of implant placement in animal test rabbits.

After surgery, the rabbits were kept in stables for 6 weeks, after which they were slaughtered with an overdose of intravenous potassium chloride solution. Subsequently, the radiological and histomorphometric study of the samples was carried out.

### 2.5. Radiological Analysis

For the radiological study, a high-quality micro-CT machine was used (Bruker preclinical Albira CT, Billerica, MA, USA). Micro-computed tomography ( $\mu$ -CT) is used to identify small objects with high-quality spatial resolution. This type of tomography is the gold standard for measuring bone microstructures and bone morphometry [18]. The 360° images were taken at maximum resolution with a 45 kV radiographic projection and an acquisition time of 30 min for each image. 2D and 3D images with 8.3 voxels/mm were generated with Imaris v.9.5 software (Bitplane, Belfast, UK). The variables analyzed were bone volume ( $\text{mm}^3$ ), mean density of bone volume (Hounsfield Units, HU), and accumulated density (Hounsfield Units, HU). The BoneJ software, which is an ImageJ plug-in (Wayne Rasband, National Institutes of Health, Bethesda, MD, USA), was used for image processing. A segmentation of the area of interest was made on every image, a threshold was applied to eliminate the “titanium” density and, later, the measurements of the three variables were made based on 1 mm of surrounding bone around a 2 mm thick space of the tibial cortical bone in transversal cuts (Figure 4).

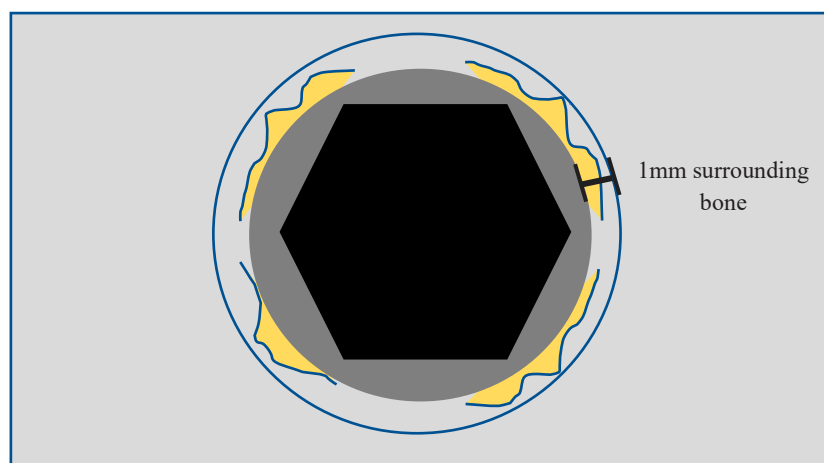
For the radiological analysis, the scheme represented in Figure 4B was followed, in which four regions were defined, two adjacent to the implant (1 mm each) and two non-adjacent to the implant (also 1 mm). For each of the variables, the results were calculated as the difference between the values obtained in non-adjacent regions and the adjacent regions. Then, the mean and standard deviation of each of the variables were calculated. This was made to avoid biases and compensate the strong artifact in the implant area.



**Figure 4.** Analysis of bone growth by micro-computed tomography ( $\mu$ -CT). Schematic representation of 3D view (A) and 2D view (B) of the dimensions of the surrounding bone that were analyzed.

### 2.6. Histomorphometric Analysis

Samples were stored in a 5% (pH 7) formaldehyde solution and after a first dissection, they were kept immersed in 4% and 1% calcium formaldehyde solution. They were mounted on a plastic slide with cyanoacrylate, sectioned at 100  $\mu$ m thickness and grinded during 5 min with sand papers of 500, 800, and 1200 grain size using a generous amount of water to cool the sections (Donath and Breuner method) [19]. After that, the samples were stained with 1% toluidine blue (TB) (Merck-Merck, Darmstadt, Germany) (histological staining as an exploratory/preliminary way) with a pH of 3.6 adjusted with HCl at 1 N. To visualize the mineralized bone, the Von Kossa (VK) technique was applied using silver nitrate (Sigma-Aldrich Chemical Co., Poole, UK). These stains were kept on the samples at room temperature for 10 min, and they were then washed with distilled water and air dried [20]. Four specimens were obtained of each type of implant. Two histological variables were measured in the Von Kossa images: bone area ( $\text{mm}^2$ ) (area of bone accounted for by a 1 mm crown around the implant) (Figure 5) and bone-implant contact, BIC (%) also measured in the region of interest described in Figure 5. BIC is a variable measured histomorphometrically and it helps to assess implant stability based on the percentage of the implant surface covered by bone [6,21]. The images were processed with ImageJ v1.50e (Wayne Rasband, National Institutes of Health, Bethesda, MD, USA). The mean and standard deviation of both variables were obtained.



**Figure 5.** Diagram of the area of bone analyzed: 1 mm around the implant surface.

### 2.7. Statistical Analysis

The comparison of the groups for each of the variables analyzed was performed using IBM SPSS Statistics 24.0 software (International Business Machines Corp; New York, NY, USA). To check the


normality in the variables, the Shapiro–Wilk test was carried out. The homogeneity of variances was verified with Levene’s test. An analysis of variance (ANOVA) was used for those variables with normality, while a Kruskal–Wallis test was carried out for those variables that did not follow normal distribution. The Bonferroni correction was used for multiple comparisons. A statistical significance level of 5% ( $p < 0.05$ ) was established.

### 3. Results

#### 3.1. Surface Characterization


##### 3.1.1. Morphological Analysis of the Surface

The Ziacom implant with the SLA surface had a rough, porous surface with numerous cavities caused by sandblasting and acid etching. Around the wells, edges were thin and sharp (Figure 6).




**Figure 6.** SEM images of the sandblasted and acid etched (SLA) surface 200× (left) and 12,000× (right).

The BioHorizons implant with sandblasted surface with hydroxyapatite and tricalcium phosphate (HA/TCP) showed an irregular surface with some randomly distributed craters and more rounded edges (Figure 7).



**Figure 7.** SEM images of the hydroxyapatite and tricalcium phosphate (HA/TCP) surface 200× (left) and 12,000× (right).

The Zimmer implant with sandblasted surface with hydroxyapatite and later washed with non-etching acid also revealed an irregular structure, with a greater number of craters, which were also randomly distributed, protuberances, and veins (Figure 8).



**Figure 8.** SEM images of the surface of HA blast, and non-etching acid wash (HA + AW) 200× (left) and 12,000× (right).

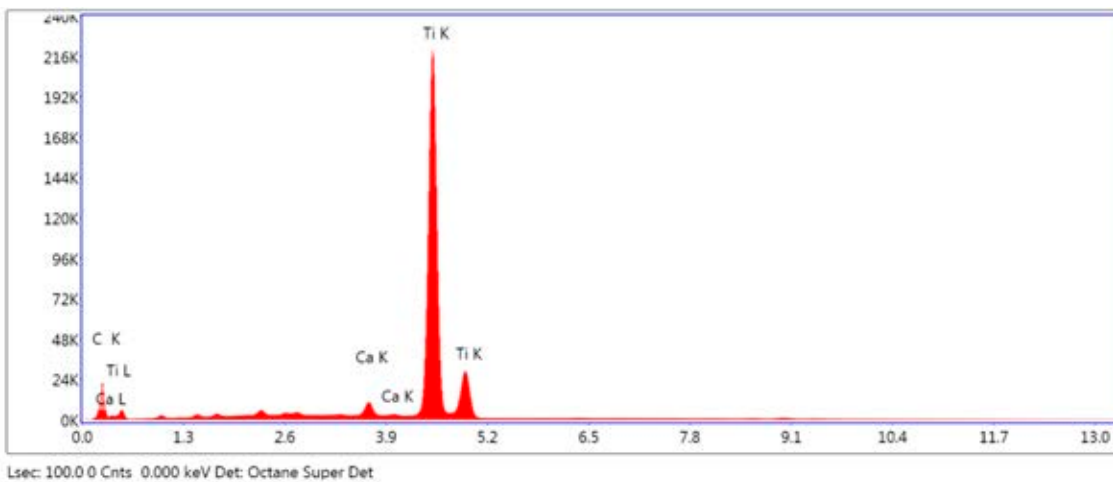
### 3.1.2. Elemental Analysis of the Surface

The compositional analysis of the different surfaces analyzed was carried out (Table 2). The percentage in elemental weight of hydrocarbon impurities detected on the surface of the HA/TCP group was much higher than that detected in the other samples. Titanium content was higher than 90% in all samples, and the HA + AW group was the group with the lower percentage. No aluminum was detected in the SLA group, due to the cleanliness of the aluminum particles from the sandblasting after the double acid etching. Ca and P are impurities derived from manufacturing. Energy dispersive spectroscopy analysis of the three surfaces is shown in Figures 9–11.

**Table 2.** Compositional analysis of implant surfaces.

Element	Weight %		
	SLA	HA/TCP	HA + AW
C K	9.38 (10.23)	5.23 (8.05)	3.91 (1.02)
Al K	-	4.60 (4.36)	3.82 (0.19)
Ti K	89.53 (11.77)	84.76 (15.59)	92.27 (0.82)

SLA, sandblasted and double acid etched.  
 HA/TCP, hydroxyapatite and tricalcium phosphate blasted.  
 HA + AW, hydroxyapatite blasted and non-etching acid wash.



**Figure 9.** Energy dispersive spectroscopy analysis of SLA.

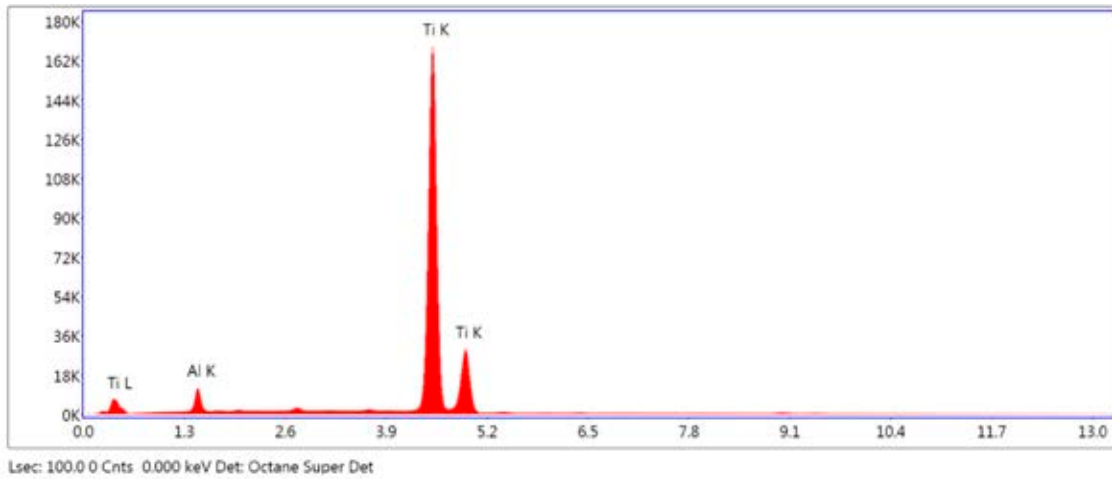


Figure 10. Energy dispersive spectroscopy analysis of HA/TCP.

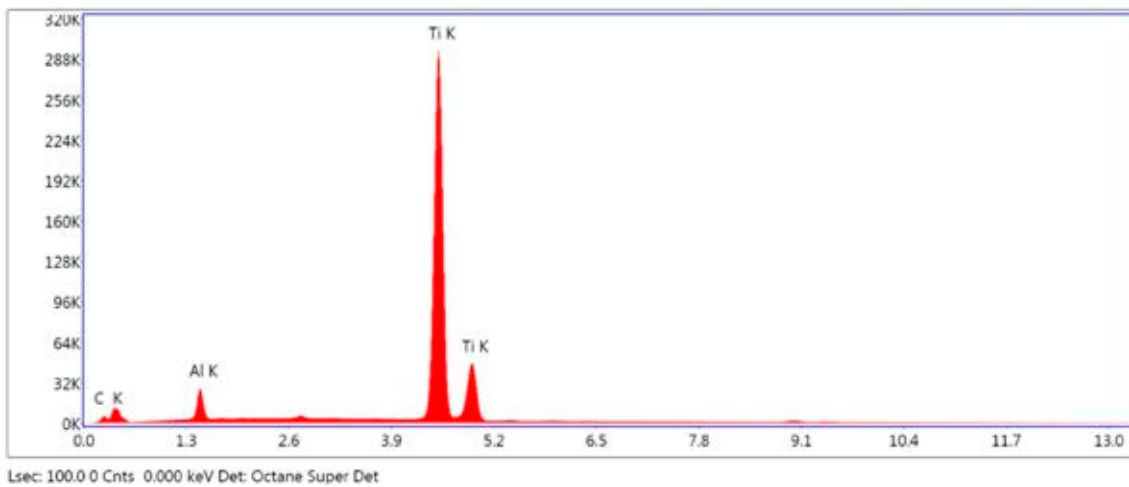


Figure 11. Energy dispersive spectroscopy analysis of HA + AW.

### 3.1.3. Analysis of Surface Profile

Profile and surface roughness parameters were measured (Tables 3 and 4). The SLA group had the lowest roughness values and the HA/TCP group had the highest. All groups presented statistically significant differences in their comparison ( $p < 0.05$ ) except in the Sv variable.

Table 3. Profile roughness parameters.

Implant	Ra ( $\mu\text{m}$ ) (SD)	Rq ( $\mu\text{m}$ ) (SD)	Rp ( $\mu\text{m}$ ) (SD)	Rv ( $\mu\text{m}$ ) (SD)
SLA	0.82 (0.10) *	0.97 (0.08) *	1.84 (0.04) **, ***	2.21 (0.01)
HA/TCP	1.11 (0.03) *	1.45 (0.10) *	2.97 (0.28) *, ***	3.38 (1.28)
HA + AW	0.97 (0.17)	1.18 (0.24)	2.07 (0.27) *, **	3.11 (0.62)

\*, \*\*, \*\*\* There are significant differences between the pairs of values identified by the same number of asterisks.

Table 4. Three-dimensional surface roughness parameters.

Implant	Sa ( $\mu\text{m}$ ) (SD)	Sq ( $\mu\text{m}$ ) (SD)	Sp ( $\mu\text{m}$ ) (SD)	Sv ( $\mu\text{m}$ ) (SD)
SLA	0.76 (0.01) **, ***	0.97 (0.01) **, ***	4.20 (0.12) *	4.62 (0.20) *, **
HA/TCP	1.61 (0.02) *, ***	2.05 (0.01) *, ***	11.69 (1.48) *	9.35 (4.02) *
HA + AW	0.92 (0.07) *, **	1.21 (0.11) *, **	10.67 (7.27)	7.97 (0.68) **

\*, \*\*, \*\*\* There are significant differences between the pairs of values identified by the same number of asterisks.

The roughness profile is represented by peaks and troughs; however, topographic distribution is different between the groups. The profile of the SLA group shows peaks and valleys in the 3–4  $\mu\text{m}$  range (Figure 12). In the case of HA/TCP, the profile is more irregular, with peaks in the 10–20  $\mu\text{m}$  range and troughs in the 4–5  $\mu\text{m}$  range (Figure 13). In the case of HA + AW, the profile is more regular but with deeper troughs in the 4–5  $\mu\text{m}$  range (Figure 14). 3D top-view roughness images were obtained. Note that intervals between peaks and valleys differ between the three surfaces and, because of that, scales are different. Amplitude scales are 0–8.5 microns for SLA, 0–24 microns for HA/TCP, and 0–13 microns for HA + AW (Figure 15).

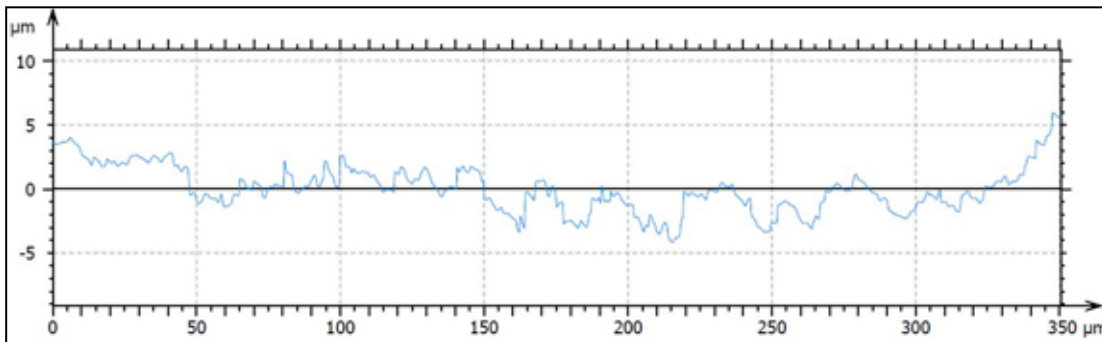


Figure 12. SLA surface profilometry.

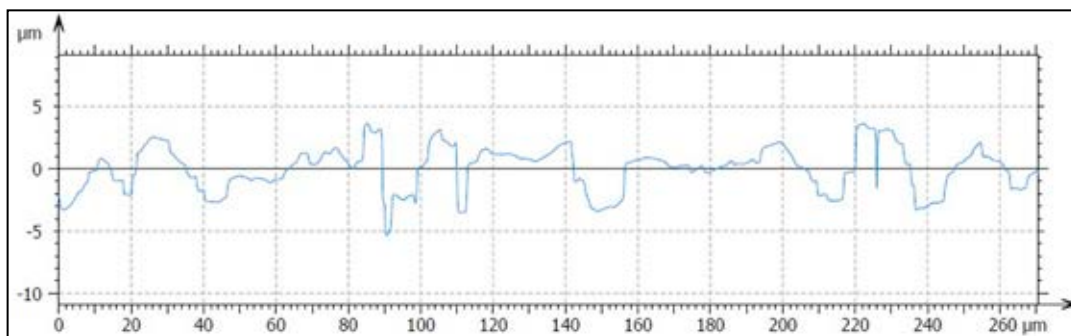


Figure 13. HA/TCP surface profilometry.

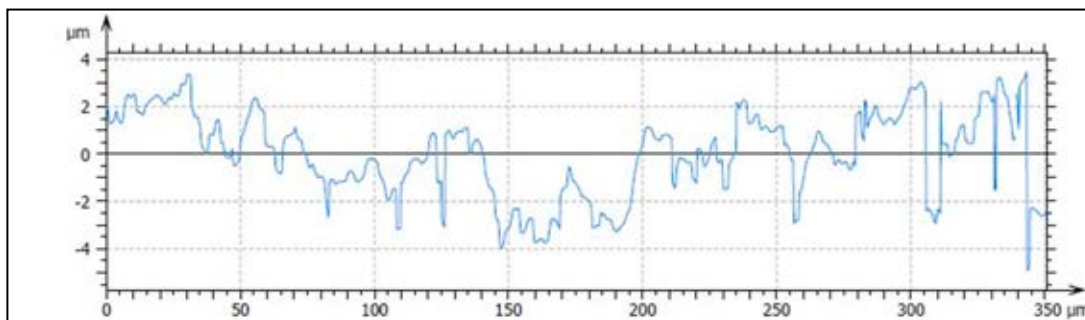


Figure 14. HA + AW surface profilometry.

### 3.2. Cell Viability Study

A cell viability study was carried out based on the percentage of mitochondrial activity at 24 h, seeding  $6 \times 10^5$  cells/surface. The JC-1 reagent allowed to evaluate the red/green ratio of mitochondrial activity based on dead cells/live cells (Figure 16). In the case of the SLA surface, a ratio of activity of 93.85 was obtained, 97.74 in the HA/TCP surface, and 96.49 in HA + AW. Mitochondrial activity was high in the three surfaces, with HA/TCP being the one with higher ratio. No statistically significant differences were observed between the three groups, nor with respect to the negative control group.



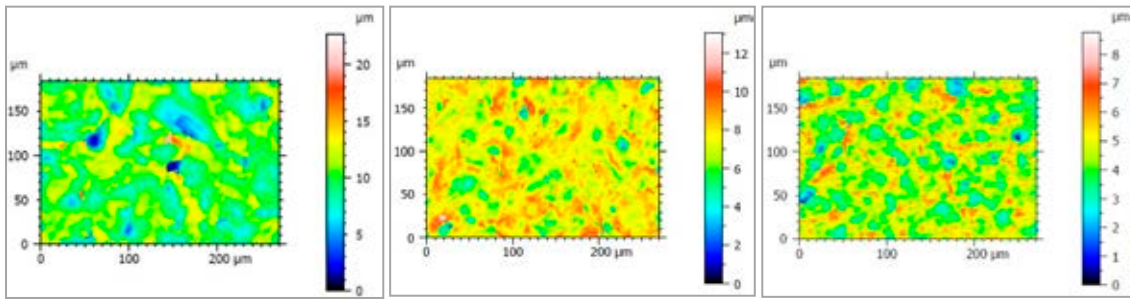


Figure 15. Color map of surface roughness in SLA (left), HA/TCP (middle), and HA + AW (right).

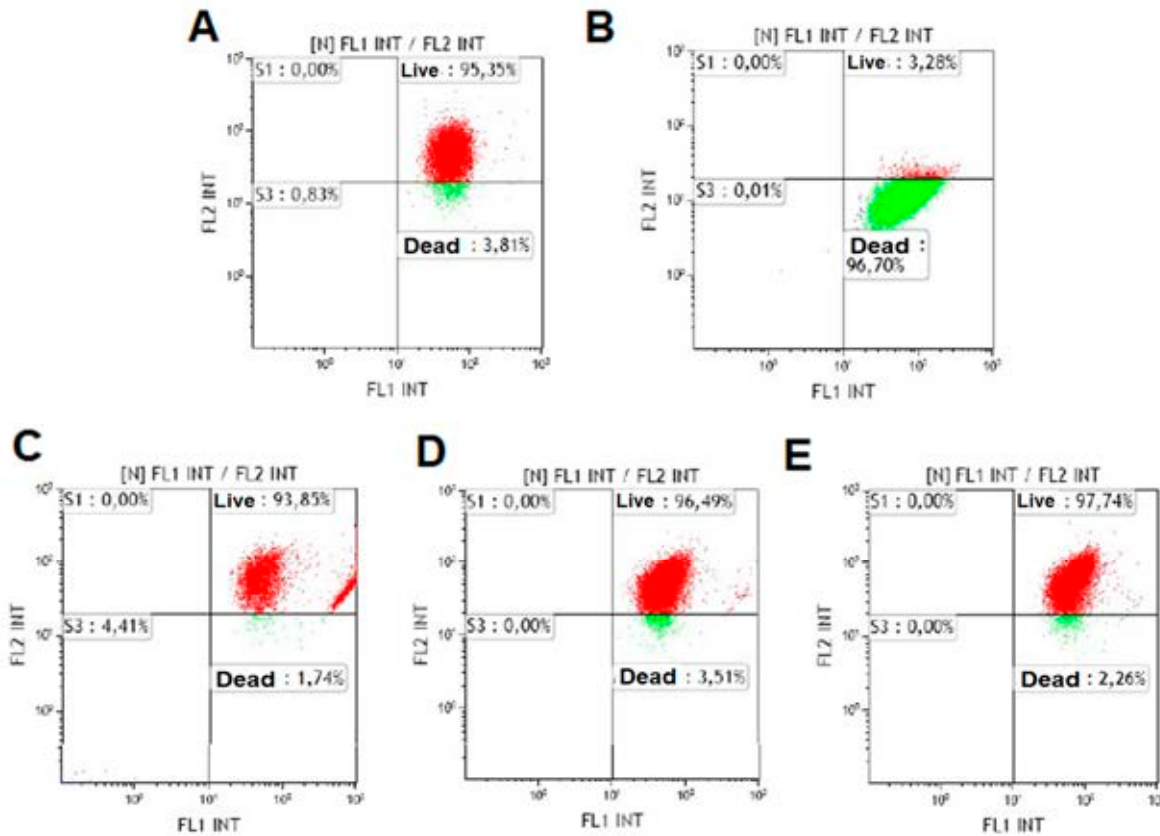


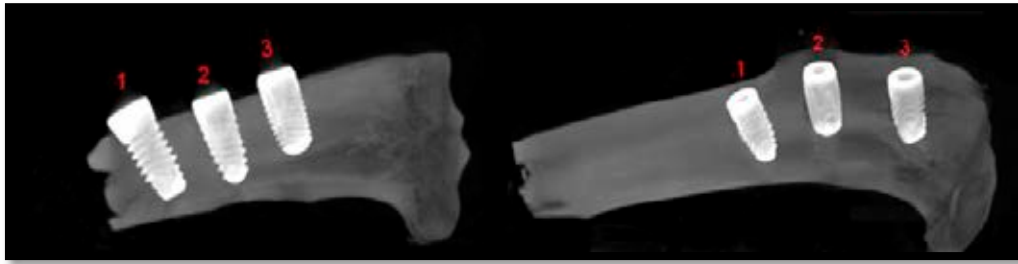
Figure 16. Balance of mitochondrial activity. (A) Negative control. (B) Positive control. (C) SLA. (D) HA + AW. (E) HA/TCP.

### 3.3. Experimental Animal Study

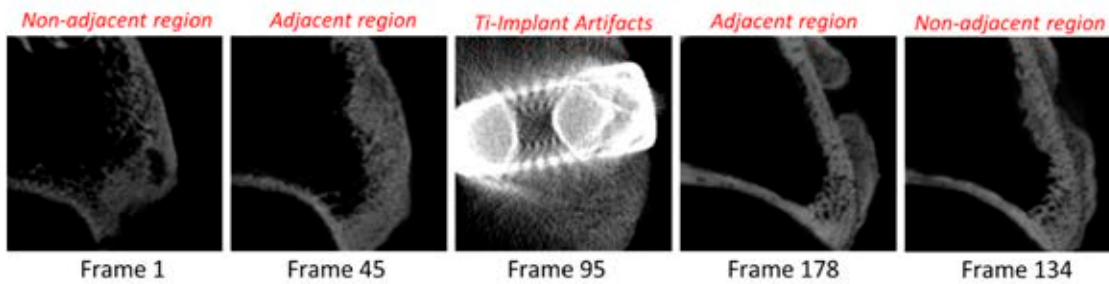
Radiological analysis was performed using micro-computed tomography (Figures 17 and 18). During this study, results obtained in relation to osseointegration indicated that radiological and histological data were favorable to Ziacom implants for the five variables studied. The bone volume, mean density, and accumulated density variables were higher in the SLA group, although not significantly so with respect to the other two groups (Table 5).

To evaluate the bone area and BIC, a histomorphometric evaluation was performed 6 weeks after implantation (Figure 19).

Regarding histological values, no significant differences were observed between the groups at the area level. The HA/TCP group had the highest BIC value, not significantly different from the SLA group. However, both groups were significantly different from HA + AW (Table 6).



**Figure 17.** Computerized microtomography of two of the tibias analyzed, in which the different types of implants used in the study are observed [1. HA/TCP (BioHorizons); 2. SLA (Ziacom); 3. HA + AW (Zimmer)].



**Figure 18.** Radiological analysis by CT imaging following implantation. The strong artefacts along the screw axis made it impossible to analyze bone structures in these positions (i.e., frame 95). To avoid biases due to this issue, results were calculated as the difference between the values obtained in non-adjacent regions (i.e., frame 1) and the adjacent regions (i.e., frame 45).

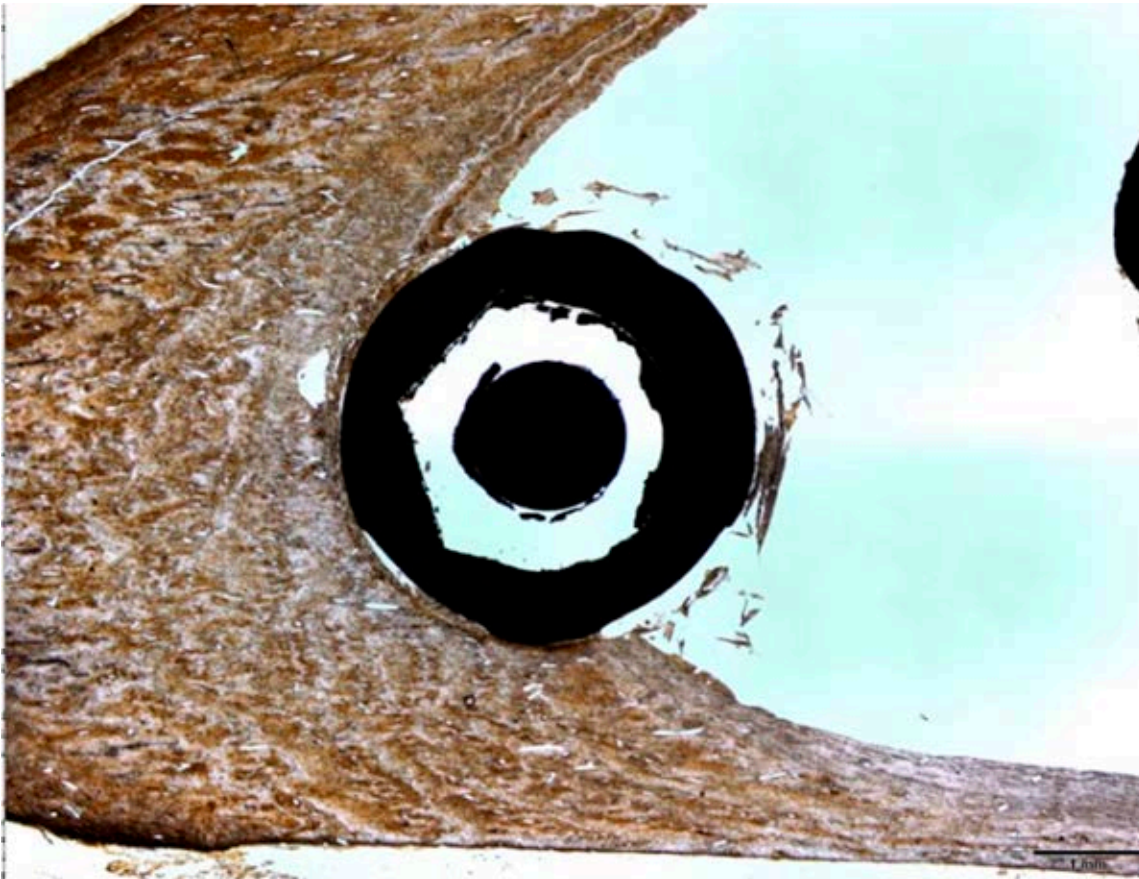
**Table 5.** Bone structure analysis data obtained with the Imaris® software.

		Mean	SD
Volume (mm <sup>3</sup> )	SLA	0.197	0.225
	HA/TCP	0.129	0.242
	HA + AW	0.009	0.007
Bone density (HU)	SLA	642.00	149.14
	HA/TCP	505.83	212.02
	HA + AW	442.25	235.28
Accumulated density (HU)	SLA	4,806,900.00	5,857,115.70
	HA/TCP	1,862,223.17	3,282,273.12
	HA + AW	233,098.00	225,000.53

**Table 6.** Data referring to the bone area and bone–implant contact (BIC).

		Mean	SD
Area (mm <sup>2</sup> )	SLA	2499	2026
	HA/TCP	3147	1978
	HA + AW	1933	1022
BIC (%)	SLA	40.6 *	17.77
	HA/TCP	41.28 **	11.26
	HA + AW	27.60 *, **	9.62

\*, \*\* There are significant differences between the pairs of values identified by the same number of asterisks.



**Figure 19.** Histological image showing mineralized bone around the HA + AW implant. Von Kossa stain, 5× magnification. The difference in the quantity of the surrounding bone (between left and right sides) is due to the location of the implant in the most distal zone of the tibial metaphysis where bone is thinner. This is an anatomical limitation because this bone has different thickness over its whole length, being thicker on the proximal zone. This image is from a distal zone of implantation. To minimize this effect in all groups, implant locations in the proximal, middle, or distal zones was alternating for reducing this possible limitation/bias.

#### 4. Discussion

This study evaluated the influence of the surface of three dental implants on the *in vitro* cellular behavior and on animal osseointegration at the level of dimensions and bone density, as well as bone–implant contact.

The detailed procedure with which this type of surface treatment is carried out is something that manufacturers do not usually publish. Therefore, this type of surface is analyzed through EDS compositional studies, roughness measurements, and morphological analysis of the surface with a scanning electron microscope.

In the case of the Ziacom SLA surface, a three-dimensional surface structure with high peaks and wide valleys was observed; this is highly effective in promoting blood activation, clot formation, and growth factor release through platelet activation [22]. This type of surface could have an osteogenic effect thanks to its different topographic characteristics at the micrometric and nanometric level, which is similar to the osteoclastic resorption wells in bone [23].

Different manufacturers develop other types of surfaces. In the case of BioHorizons, the RBT<sup>®</sup> surface is based on sandblasting with synthetic resorbable bioceramic particles, such as titanium dioxide, hydroxyapatite, or tricalcium phosphate particles, to make the surface rougher [24,25]. The presence of these particles, which some of them are naturally part of the mineral bone phase, seeks to improve and

accelerate the osseointegration phase [10]. Traditionally, sandblasting has been done with alumina, but there may be remains on the surface of the implant that hinder osseointegration, which is why the sandblasting method with resorbable bioceramic materials emerged years ago [26]. Furthermore, there is currently no consensus on this issue. While some authors argue that residual aluminum oxide has no effect on osseointegration [27], some others argue that it could become impregnated at the surface and hinder osseointegration. According to the published literature, this may be due to the Al ions competition action to calcium during the healing of implant bed and therefore producing inhibition of normal differentiation of bone marrow stromal cells and normal bone deposition and mineralization [28,29].

The main reason for selecting resorbable ceramic particles is that they remain on the surface and can absorb proteins such as fibrinogen and other serum proteins involved in platelet activation. The type of structure observed in the SEM analysis showed a markedly irregular surface with sharp-edged craters.

Zimmer MTX<sup>®</sup> surface is based on the combination of HA-blasting, an acid wash without etching and distilled water to remove material from sandblasting [30]. The observed surface showed an irregular topography with multiple craters and veins. This surface treatment intends to unify the benefits of both types of treatment (ceramic sandblasting and acid wash), although acid wash generates a different surface than acid etching, which resulted in the lowest BIC value in our study.

Surface roughness is a factor with a decisive influence on the balance between bone formation and resorption at the bone–implant interface, and therefore on its stability [31]. The profilometric study revealed that the surface with the highest profile and surface roughness was the HA/TCP group. According to the Albrektsson and Wennerberg classification, the HA/TCP group would show a surface with moderate roughness (Sa: 1–2 µm) and the other two groups would show minimum roughness (Sa: 0.5–1 µm). This moderate roughness is considered optimal to promote osseointegration [32]. Rp and Sp parameters are related to Ra and Sa and are important components in outstanding peaks and valleys, which increase the average roughness value.

The fact that the HA/TCP surface has the highest roughness is due to the fact that it is only sandblasted, which is the procedure that achieves the highest roughness. The other two groups (SLA and HA + AW) have less roughness, which would be due to the etching or acid washing treatment.

Viability was evaluated on MG-63 osteoblastic cells, which are used commonly to carry out this type of study [33]. A JC-1 test was performed to determine the mitochondrial activity ratio. Although it is true that the rougher surfaces show greater adhesion, proliferation, and osteoblastic differentiation [6,33], no statistically significant differences were observed at the level of cell viability despite the differences in topography and surface roughness. All three surfaces are considered to be biocompatible.

Implant stability depends on the bone density surrounding the implant as well as the bone–implant contact [5]. This last factor is linked to the transition from primary to secondary implant stability, obtained by the progression from a mechanical bond to the biological bond of new bone positioned on the implant surface at the end of the osseointegration period, which was a 6-week period in our study.

The bone deposited on the surface irregularities of the implant and in the chambers that form between the spirals of the implants matures and increases in volume and density through the formation of a greater number of blood vessels after 4 weeks [34]. Our study is not a “chambers” type as we used commercial implants, so new bone cannot be evaluated. Von Kossa stain is not able to detect new bone but only mineralized bone which is one of the aims of the study. New bone could be seen weeks before osseointegration, but this was not the goal of our study as it was evaluated after 6 weeks of implantation, considering this point in time as the end of the osseointegration process.

According to the literature reviewed, the maximum percentage of bone–implant contact is approximately 60%. Environmental contamination particles were detected on the EDS of the SLA surface (calcium and phosphorus) [35]. This contamination is inevitable and may also be due to the deposition of carbon impurities on the surface of the implant, which affects the complete adaptation of the bone–implant surface [35,36]. However, in this study, the HA/TCP group presented a higher

percentage of carbon (18.46%) and was also the one with the highest BIC. Conversely, the HA + AW group obtained a significantly lower BIC value but with a carbon percentage of only 2.14%; it also had the lowest percentage of titanium of the three groups (91.69%). It is therefore reasonable to think that carbon accumulation did not have a determining influence, as has been observed in other studies [23]. In the same way, it can be stated that it did not influence either the cell viability or the bone variables analyzed. Although, EDS may not prove to be the most suitable method for measuring hydrocarbon impurities, X-ray photoelectron spectroscopy (XPS) should have been conducted.

The HA + AW group had significantly lower roughness than the other two groups, and its BIC value was also the lowest of the three. These BIC values are in accordance with roughness results, with HA/TCP and HA + AW being the groups with better profile and surface parameters (Ra, Rp, Rq, Rv, Sa, Sp, Sq, and Sv). These parameters define the surface microtopography and the latter has a key role in osseointegration [13], although some authors consider Sds and Sdr better options [37]. For this reason, this is considered a limitation of the study, since these additional parameters offer a better understanding of the surface microtopography.

These types of surfaces have often been compared in the literature. Fabbro et al. compared commercially pure titanium implants with HA blasting and subsequent acid etching (HA + AE), which were placed on mini pigs. BIC was analyzed in the coronal area. A total of 80.79% was obtained in the SLA group and 83.53% in the HA + AE group, without statistically significant differences between both [38]. These values are much higher than those obtained in our study, in which our comparable surfaces obtained values of 40.6% (SLA) and 27.60% (HA + AW); a statistically significant difference between both groups was observed.

Another study compared sandblasted surfaces with biphasic tricalcium phosphate (BCP) and surfaces with SLA treatment on implants placed in rabbits. BIC was evaluated at 8 weeks and SLA ( $\approx 68\%$ ) was found to have a significantly higher BIC value than BCP ( $\approx 47\%$ ). These authors explain these results by the fact that BCP-type surfaces are not treated with acid etching and, therefore, do not create a nanometer-scale topography, which would favor the adhesion and proliferation of osteoblasts [23]. In our study, no statistically significant difference was observed between both groups at the BIC level, as in other studies found in the literature [39–42].

Lukaszewska-Kuska et al. developed an in vitro study in which they compared titanium discs with different treatments similar to those carried out in this study: SLA, HA/TCP, and HA/TCP + acid etching. It is important to be cautious when comparing, since the latter group was sandblasted with TCP and then acid etched, unlike our HA + AW group which only has sandblasting with HA and washing with non-etching acid. As in our study, a viability test with MTS was carried out after 24 h. No statistically significant differences were observed between the groups [43].

Differences found in BIC when compared to other studies may be due, among other factors, to the fact that different animals are used (mini pigs, goats, dogs, or rats) whose bone characteristics may not be similar. Furthermore, the site of implantation may vary from one study to another (more or less trabecular or cortical area); therefore, comparisons between publications should be analyzed with caution.

To assess the results of our study, the macrodesign characteristics of each type of implants must also be integrated, although this has not been the primary objective of our study. For example, primary or mechanical stability depends mainly on three factors: the surgical procedure applied (relationship between the size of the implant and the surgical site prepared), bone density, and the design of the implant at both a macro and microscopic level [44].

On the other hand, the different elements of the implant (neck, body, and apical region), in addition to having the mission of procuring greater primary stability to the implant, are also involved in promoting the transmission of masticatory forces in the most homogeneous and natural way possible, as well as maintain a biological environment as compatible as possible with the function of dental implants [45,46].

Finally, the three groups showed good osseointegration according to the values obtained in terms of dimensions and bone density. The SLA group showed higher values in terms of bone volume, mean density, and accumulated density, although not significantly in comparison to the other two groups. Similarly, no significant differences were observed between the groups at the area level. In this sense, similar and good bone behavior can be observed in both pure titanium and alloy. In addition, there was also agreement between the in vitro study of cell viability and the in vivo histometric and bone density study.

## 5. Conclusions

This work evaluated the surface characteristics of several implants available in the market, as well as in vitro cell viability and their effect on different bone variables such as bone density and bone–implant contact. SLA and HA/TCP surfaces were the ones that obtained a higher BIC value. In the in vitro cell viability study, no statistically significant differences between the groups were observed. Likewise, no significant differences were observed at the level of volume, bone density, accumulated bone density, or area.

It is important to consider cautiously the results obtained, since this in vivo study with animals was carried out only during the osseointegration period (6 weeks) and parameters such as BIC could change over time. Therefore, in order to have evidence, more studies are needed to extend the study time.

**Author Contributions:** Conceptualization, M.-A.S.-F. and D.T.-L.; Formal analysis, M.R.-G., A.G.-d.-F. and J.-L.G.-P.; Funding acquisition, D.T.-L.; Investigation, M.R.-G., I.F.-A., A.G.-d.-F., C.V.-P., M.-A.S.-F., D.T.-L. and J.-L.G.-P.; Methodology, I.F.-A., A.G.-d.-F., M.-A.S.-F., D.T.-L. and J.-L.G.-P.; Project administration, J.-L.G.-P.; Resources, C.V.-P.; Validation, M.R.-G., M.-A.S.-F. and D.T.-L.; Writing—original draft, M.R.-G., I.F.-A., A.G.-d.-F., C.V.-P., M.-A.S.-F., D.T.-L. and J.-L.G.-P.; Writing—review and editing, M.R.-G., I.F.-A., A.G.-d.-F., C.V.-P., M.-A.S.-F., D.T.-L. and J.-L.G.-P. All authors have read and agreed to the published version of the manuscript.

**Funding:** This research was funded by Ziacom Medical SLU® (Madrid, Spain)—Grant FISEVI 2017.

**Acknowledgments:** The authors would like to express our gratitude to the technical staff of CITIUS-Central Research Services of the University of Seville.

**Conflicts of Interest:** The authors declare no conflict of interest. The funders had no role in the design of the study; in the collection, analyses, or interpretation of data; in the writing of the manuscript, or in the decision to publish the results.

## References

1. Albrektsson, T.; Wennerberg, A. On osseointegration in relation to implant surfaces. *Clin. Implant Dent. Relat. Res.* **2019**, *21* (Suppl. 1), 4–7. [[CrossRef](#)]
2. Babík, O.; Czán, A.; Holubjak, J.; Kameník, R.; Pilc, J. Identification of Surface Characteristics Created by Miniature Machining of Dental Implants Made of Titanium Based Materials. *Procedia Eng.* **2017**, *192*, 1016–1021. [[CrossRef](#)]
3. Saini, M.; Singh, Y.; Arora, P.; Arora, V.; Jain, K. Implant biomaterials: A comprehensive review. *World J. Clin. Cases* **2015**, *3*, 52–57. [[CrossRef](#)] [[PubMed](#)]
4. Elias, C.N.; Fernandes, D.J.; Resende, C.R.; Roestel, J. Mechanical properties, surface morphology and stability of a modified commercially pure high strength titanium alloy for dental implants. *Dent. Mater.* **2015**, *31*, e1–e13. [[CrossRef](#)]
5. Bosshardt, D.D.; Chappuis, V.; Buser, D. Osseointegration of titanium, titanium alloy and zirconia dental implants: Current knowledge and open questions. *Periodontol 2000* **2017**, *73*, 22–40. [[CrossRef](#)] [[PubMed](#)]
6. Annunziata, M.; Guida, L. The Effect of Titanium Surface Modifications on Dental Implant Osseointegration. *Front. Oral Biol.* **2015**, *17*, 62–77.
7. Stanford, C.M. Surface modifications of dental implants. *Aust. Dent. J.* **2008**, *53* (Suppl. 1), S26–S33. [[CrossRef](#)]
8. Patil, P.; Bhongade, M. Dental Implant Surface Modifications: A Review. *J. Dent. Med. Sci.* **2016**, *15*, 132–141.
9. Jemat, A.; Ghazali, M.J.; Razali, M.; Otsuka, Y. Surface Modifications and Their Effects on Titanium Dental Implants. *BioMed Res. Int.* **2015**, *2015*, 791725. [[CrossRef](#)]

10. Park, N.I.; Kerr, M. Chapter 9: Dental Implant Surfaces. In *Misch's Contemporary Implant Dentistry*, 4th ed.; Resnik, R., Ed.; Elsevier: Amsterdam, The Netherlands, 2020; p. 197.
11. Barfeie, A.; Wilson, J.; Rees, J. Implant surface characteristics and their effect on osseointegration. *Br. Dent. J.* **2015**, *218*, E9. [[CrossRef](#)]
12. Massaro, C.; Rotolo, P.; De Riccardis, F.; Milella, E.; Napoli, A.; Wieland, M.; Textor, M.; Spencer, N.D.; Brunette, D.M. Comparative investigation of the surface properties of commercial titanium dental implants. Part I: Chemical composition. *J. Mater. Sci. Mater. Med.* **2002**, *13*, 535–548. [[CrossRef](#)] [[PubMed](#)]
13. Smeets, R.; Stadlinger, B.; Schwarz, F.; Beck-Broichsitter, B.; Jung, O.; Precht, C.; Kloss, F.; Gröbe, A.; Heiland, M.; Ebker, T. Impact of Dental Implant Surface Modifications on Osseointegration. *Biomed. Res. Int.* **2016**, *2016*, 6285620. [[CrossRef](#)]
14. Hemlata, G.; Gaurav, B.; Arvind, G. Implant Surface Modifications: A Review. *J. Clin. Diagn. Res.* **2012**, *6*, 319–324.
15. Park, J.Y.; Davies, J.E. Red blood cell and platelet interactions with titanium implant surfaces. *Clin. Oral Implants Res.* **2000**, *11*, 530–539. [[CrossRef](#)]
16. Bornstein, M.M.; Reichart, P.A.; Buser, D.; Bosshardt, D.D. Tissue response and wound healing after placement of two types of bioengineered grafts containing vital cells in submucosal maxillary pouches: An experimental pilot study in rabbits. *Int. J. Oral Maxillofac. Implants* **2011**, *26*, 768–775.
17. Castillo-Dalí, G.; Castillo-Oyagüe, R.; Terriza, A.; Saffar, J.L.; Batista-Cruzado, A.; Lynch, C.D.; Sloan, A.J.; Gutiérrez-Pérez, J.L.; Torres-Lagares, D. Pre-prosthetic use of poly (lactic-co-glycolic acid) membranes treated with oxygen plasma and TiO<sub>2</sub> nanocomposite particles for guided bone regeneration processes. *J. Dent.* **2016**, *47*, 71–79. [[CrossRef](#)] [[PubMed](#)]
18. Bouxsein, M.L.; Boyd, S.K.; Christiansen, B.A.; Guldberg, R.E.; Jepsen, K.J.; Müller, R. Guidelines for assessment of bone microstructure in rodents using micro-computed tomography. *J. Bone Miner. Res.* **2010**, *25*, 1468–1486. [[CrossRef](#)] [[PubMed](#)]
19. Donath, K.; Breuner, G. A method for the study of undecalcified bones and teeth with attached soft tissues. The Säge-Schliff (sawing and grinding) technique. *J. Oral Pathol.* **1982**, *11*, 318–326. [[CrossRef](#)] [[PubMed](#)]
20. Torres-Lagares, D.; Castellanos-Cosano, L.; Serrera-Figallo, M.Á.; García-García, F.J.; López-Santos, C.; Barranco, A.; Rodríguez-Gonzalez Elipse, A.; Rivera-Jiménez, C.; Gutiérrez-Pérez, J.L. In Vitro and in Vivo Study of Poly (Lactic-co-Glycolic) (PLGA) Membranes Treated with Oxygen Plasma and Coated with Nanostructured Hydroxyapatite Ultrathin Films for Guided Bone Regeneration Processes. *Polymers* **2017**, *9*, 410. [[CrossRef](#)]
21. Bernhardt, R.; Kuhlisch, E.; Schulz, M.C.; Eckelt, U.; Stadlinger, B. Comparison of bone-implant contact and bone-implant volume between 2D-histological sections and 3D-SRμCT slices. *Eur. Cell Mater.* **2012**, *23*, 237–247. [[CrossRef](#)]
22. Kim, H.; Choi, S.H.; Ryu, J.J.; Koh, S.Y.; Park, J.H.; Lee, I.S. The biocompatibility of SLA-treated titanium implants. *Biomed. Mater.* **2008**, *3*, 025011. [[CrossRef](#)] [[PubMed](#)]
23. Le Guehennec, L.; Goyenvalle, E.; Lopez-Heredia, M.A.; Weiss, P.; Amouriq, Y.; Layrolle, P. Histomorphometric analysis of the osseointegration of four different implant surfaces in the femoral epiphyses of rabbits. *Clin. Oral Implants Res.* **2008**, *19*, 1103–1110. [[CrossRef](#)] [[PubMed](#)]
24. Coelho, P.G.; Granjeiro, J.M.; Romanos, G.E.; Suzuki, M.; Silva, N.R.; Cardaropoli, G.; Thompson, V.P.; Lemons, J.E. Basic research methods and current trends of dental implant surfaces. *J. Biomed. Mater. Res. B* **2009**, *88*, 579–596. [[CrossRef](#)] [[PubMed](#)]
25. Yoon, W.J.; Kim, S.G.; Oh, J.S.; You, J.S.; Jeong, K.I.; Lim, S.C.; Jeong, M.A. Comparative study on the osseointegration of implants in dog mandibles according to the implant surface treatment. *J. Korean Assoc. Oral Maxillofac. Surg.* **2016**, *42*, 345–351. [[CrossRef](#)]
26. Citeau, A.; Guicheux, J.; Vinatier, C.; Layrolle, P.; Nguyen, T.P.; Pilet, P.; Daculsi, G. In vitro biological effects of titanium rough surface obtained by calcium phosphate grid blasting. *Biomaterials* **2005**, *26*, 157–165. [[CrossRef](#)]
27. Piattelli, A.; Degidi, M.; Paolantonio, M.; Mangano, C.; Scarano, A. Residual aluminum oxide on the surface of titanium implants has no effect on osseointegration. *Biomaterials* **2003**, *24*, 4081–4089. [[CrossRef](#)]
28. Gehrke, S.A.; Taschieri, S.; Del Fabbro, M.; Coelho, P.G. Positive Biomechanical Effects of Titanium Oxide for Sandblasting Implant Surface as an Alternative to Aluminium Oxide. *J. Oral Implantol.* **2015**, *41*, 515–522. [[CrossRef](#)]

29. Esposito, M.; Hirsch, J.M.; Lekholm, U.; Thomsen, P. Biological factors contributing to failures of osseointegrated oral implants. (II). Etiopathogenesis. *Eur. J. Oral Sci.* **1998**, *106*, 721–764. [[CrossRef](#)]
30. Shafie, H.R.; Ballard, M.L. Abutment Preparation Techniques for One-Piece Titanium and Zirconia Implants. In *Clinical and Laboratory Manual of Dental Implant Abutments*; Shafie, H.R., Ed.; Wiley Blackwell: Hoboken, NJ, USA, 2014.
31. Sezin, M.; Croharé, L.; Ibañez, J.C. Microscopic Study of Surface Microtopographic Characteristics of Dental Implants. *Open Dent. J.* **2016**, *10*, 139–147. [[CrossRef](#)]
32. Albrektsson, T.; Wennerberg, A. Oral implant surfaces: Part 1—Review focusing on topographic and chemical properties of different surfaces and in vivo responses to them. *Int. J. Prosthodont.* **2004**, *17*, 536–543.
33. Bachle, M.; Kohal, R.J. A systematic review of the influence of different titanium surfaces on proliferation, differentiation and protein synthesis of osteoblast-like MG63 cells. *Clin. Oral Implants Res.* **2004**, *15*, 683–692. [[CrossRef](#)]
34. Buser, D.; Broggin, N.; Wieland, M.; Schenk, R.K.; Denzer, A.J.; Cochran, D.L.; Hoffmann, B.; Lussi, A.; Steinemann, S.G. Enhanced bone apposition to a chemically modified SLA titanium surface. *J. Dent. Res.* **2004**, *83*, 529–533. [[CrossRef](#)]
35. Hayashi, R.; Ueno, T.; Migita, S.; Tsutsumi, Y.; Doi, H.; Ogawa, T.; Hanawa, T.; Wakabayashi, N. Hydrocarbon Deposition Attenuates Osteoblast Activity on Titanium. *J. Dent. Res.* **2014**, *93*, 698–703. [[CrossRef](#)]
36. Ogawa, T.; Nishimura, I. Different bone integration profiles of turned and acid-etched implants associated with modulated expression of extracellular matrix genes. *Int. J. Oral Maxillofac. Implants* **2003**, *18*, 200–210.
37. Rosa, M.B.; Albrektsson, T.; Francischone, C.E.; Schwartz Filho, H.O.; Wennerberg, A. The influence of surface treatment on the implant roughness pattern. *J. Appl. Oral Sci.* **2012**, *20*, 550–555. [[CrossRef](#)]
38. Fabbro, M.D.; Taschieri, S.; Canciani, E.; Addis, A.; Musto, F.; Weinstein, R.; Dellavia, C. Osseointegration of Titanium Implants With Different Rough Surfaces: A Histologic and Histomorphometric Study in an Adult Minipig Model. *Implant Dent.* **2017**, *26*, 357–366. [[CrossRef](#)]
39. Dundar, S.; Yaman, F.; Bozoglan, A.; Yildirim, T.T.; Kirtay, M.; Ozupek, M.F.; Artas, G. Comparison of Osseointegration of Five Different Surfaced Titanium Implants. *J. Craniofac. Surg.* **2018**, *29*, 1991–1995. [[CrossRef](#)]
40. Coelho, P.G.; Bonfante, E.A.; Pessoa, R.S.; Marin, C.; Granato, R.; Giro, G.; Witek, L.; Suzuki, M. Characterization of five different implant surfaces and their effect on osseointegration: A study in dogs. *J. Periodontol.* **2011**, *82*, 742–750. [[CrossRef](#)]
41. Bonfante, E.A.; Marin, C.; Granato, R.; Suzuki, M.; Hjerpppe, J.; Witek, L.; Coelho, P.G. Histologic and biomechanical evaluation of alumina-blasted/acid-etched and resorbable blasting media surfaces. *J. Oral Implantol.* **2012**, *38*, 549–557. [[CrossRef](#)]
42. Marin, C.; Granato, R.; Suzuki, M.; Janal, M.N.; Gil, J.N.; Nemcovsky, C.; Bonfante, E.A.; Coelho, P.G. Biomechanical and histomorphometric analysis of etched and non-etched resorbable blasting media processed implant surfaces: An experimental study in dogs. *J. Mech. Behav. Biomed. Mater.* **2010**, *3*, 382–391. [[CrossRef](#)]
43. Lukaszewska-Kuska, M.; Wirstlein, P.; Majchrowski, R.; Dorocka-Bobkowska, B. Osteoblastic cell behaviour on modified titanium surfaces. *Micron* **2018**, *105*, 55–63. [[CrossRef](#)]
44. Azcarate-Velázquez, F.; Castillo-Oyagüe, R.; Oliveros-López, L.G.; Torres-Lagares, D.; Martínez-González, A.J.; Pérez-Velasco, A.; Lynch, C.D.; Gutiérrez-Pérez, J.L.; Serrera-Figallo, M.A. Influence of bone quality on the mechanical interaction between implant and bone: A finite element analysis. *J. Dent.* **2019**, *88*, 103161. [[CrossRef](#)]
45. Scarano, A.; Degidi, M.; Perrotti, V.; Degidi, D.; Piattelli, A.; Iezzi, G. Experimental evaluation in rabbits of the effects of thread concavities in bone formation with different titanium implant surfaces. *Clin. Implant Dent. Relat. Res.* **2014**, *16*, 572–581. [[CrossRef](#)]
46. Scarano, A.; Lorusso, C.; Di Giulio, C.; Mazzatenta, A. Evaluation of the Sealing Capability of the Implant Healing Screw by Using Real Time Volatile Organic Compounds Analysis: Internal Hexagon Versus Cone Morse. *J. Periodontol.* **2016**, *87*, 1492–1498. [[CrossRef](#)]



© 2020 by the authors. Licensee MDPI, Basel, Switzerland. This article is an open access article distributed under the terms and conditions of the Creative Commons Attribution (CC BY) license (<http://creativecommons.org/licenses/by/4.0/>).





# Implant Dentistry

Date: 2019

Page: 279 - 281 VOLUME 28, NUMBER 3 2019

Country: UK

Article name: FREQUENCY VALUES AND THEIR RELATIONSHIP  
WITH THE DIAMETER OF DENTAL IMPLANTS.  
PROSPECTIVE STUDY OF 559 IMPLANTS

Products: Zinic®

Dentist: Juan Manuel Aragoneses  
Ana Suárez  
Vanessa Arlette Brugal  
Margarita Gómez



# Frequency Values and Their Relationship With the Diameter of Dental Implants. Prospective Study of 559 Implants

Juan Manuel Aragoneses, MD, DDS, PhD,\* Ana Suárez, PhD,† Vanessa Arlette Brugal, DDS,‡ and Margarita Gómez, PhD§

**D**ental implants have proven to be a viable, highly predictable option for supporting prosthetic rehabilitations. Thanks to the phenomenon of osseointegration, they rehabilitate missing teeth.<sup>1</sup>

To achieve said osseointegration, primary stability is of the essence.<sup>2</sup> It is acquired by surgically preparing the implant bed and inserting the implant. Osseointegration is defined as the implant's resistance to movement from axial, lateral, and rotational forces and is dependent on a number of factors: the implant's macroscopic design, the surgical technique, and bone density.<sup>3-6</sup>

During the healing period, a remodeling of the bone tissue occurs, and bone apposition can be observed between the implant's threads. This results from an increase in the bone-implant interface<sup>7</sup> known as secondary stability. On a clinical level, this was initially characterized as decreased

**Purpose:** The purpose of this prospective study is to evaluate the relationship between implant diameter, and primary and secondary stability.

**Materials and methods:** Five hundred fifty-nine implants with diameters of 3.7, 4.0, and 4.3 mm and lengths of 10 and 11.5 mm were placed in 195 patients. The resonance frequency was measured during surgery and at 3, 6, and 12 months.

**Results:** Related average implant stability quotient (ISQ) values were 69.62 for 3.7-mm implants, 72.02 for 4.0-mm implants, and 69.67 for 4.3-mm implants. Values in men were greater than values in

women. Values were greater for the mandible than for the maxilla. There are significant differences between 4.0-mm implants, and 3.7 anterior maxilla and 4.3 posterior maxilla.

**Conclusions:** There is no relationship between increased ISQ values and increased diameters. We observed a preference regarding sex, with men having significantly greater values for 3.7- and 4.3-mm diameters. The mandible obtained the greatest ISQ values, with significant differences for diameters 3.7 and 4.3 mm. (Implant Dent 2019;28:279-288)

**Key Words:** implant diameter, primary and secondary implant stability, implant stability quotient

\*Research Director, School of Dentistry, Federico Henríquez y Carvajal University, Santo Domingo, Dominican Republic.  
†Clinical Coordinator, Professor, Department of Clinical Dentistry, School of Biomedical Sciences, European University of Madrid, Madrid, Spain.  
‡Titular Professor, Department of Paediatric Dentistry and Orthopedics, School of Dentistry, Autonomous University of Santo Domingo, Santo Domingo, Dominican Republic.  
§Head of Department of Dentistry, Professor, School of Biomedical Sciences, European University of Madrid, Madrid, Spain.

Reprint requests and correspondence to: Ana Suárez, PhD, Department of Clinical Dentistry, School of Biomedical Sciences, European University of Madrid, Policlínica Universitaria, Plaza Francisco Morano s/n. Madrid 2005, Spain, Phone: 0034-91-3858826, Fax: 0034-91-3858826, E-mail: ana.suarez@universidadeuropea.es

ISSN 1056-6163/19/02803-279  
Implant Dentistry  
Volume 28 • Number 3  
Copyright © 2019 Wolters Kluwer Health, Inc. All rights reserved.

DOI: 10.1097/ID.0000000000000887

primary stability, critical period during which there is an increased risk of micromovements, which may lead to deficient osseointegration.<sup>8</sup> As such, it is important to have at one's disposal diagnostic tools that will allow one to establish the minimum implant stability necessary, so as to reduce the risk of micromovements and any complications resulting from them during the process.<sup>9</sup>

One of the most widely used methods for analyzing primary and secondary stability is the resonance frequency analysis (RFA).<sup>10-13</sup> It is a noninvasive diagnostic system that evaluates the rigidity of the bone-implant interface

to assign quantitative values. With these values, once is able to evaluate, albeit indirectly, the implant's stability. The most recent RFA system for clinical use is Ostell Mentor (Osstell AB, Gothenburg, Sweden), which uses a transducer (SmartPeg) screwed into the implant. The implant can be accessed through electromagnetic pulses generated by a portable device, which gathers numerical values corresponding to the so-called implant stability quotient (ISQ). These values can range from 1 to 100, with one representing very little stability. Furthermore, this system allows one to repeat and reproduce values almost perfectly.<sup>9</sup>

A number of studies have already established a correlation between the ISQ values and the implant's degree of mobility regarding the bone tissue.<sup>11,14–16</sup> Different variables may come into play, such as bone quantity and quality, surgical technique, and the implant's geometry, the length and the diameter.<sup>14,17–22</sup> Also to be taken into account is the correlation between ISQ values and the healing processes from the implant's osseointegration, resulting in a positive prognosis.<sup>23–28</sup>

Given the discrepancy in the existing literature regarding the geometric factors, specifically the implants' diameter, which may impact primary stability, our objective in this study is to evaluate the role diameter plays in the primary and secondary stability of dental implants, using the RFA (*in vivo*) as our basis.

## MATERIALS AND METHODS

### Study Group

This prospective study was conducted at the Universidad Federico Henríquez y Carvajal's (UFHEC) postgraduate university clinic from 2016 to 2018.

To be able to participate in the study, the following inclusion and exclusion criteria were applied:

### Inclusion Criteria

- ASA I patients
- Patients missing 1 or more teeth (mandible or maxilla)
- Patients with no active periodontal disease.
- Patients with sufficient bone quantity for the length and diameter of the implants (measured with CBCT using a surgical stent to establish implant placement site).
- Edentulous spaces with sufficient keratinized gingiva.
- Posterior rehabilitation with cemented crowns or bridges.
- No need for bone or mucosal regeneration.

### Exclusion Criteria

- Patients who did not meet the inclusion criteria.
- Smokers.
- Patients who did not wish to participate in the study.
- Patients with ASA II classification or higher.

- Patients undergoing treatment or who have received treatment with bisphosphonates.
- Patients who have undergone or are undergoing chemotherapy.
- Patients who are undergoing anti-metabolic therapy.
- Pregnant women.
- Patients who had been treated with antibiotics in the 3 months before the first surgery.
- Toothless patients.
- Patients requiring additional bone regeneration surgery during implant insertion.
- Patients diagnosed at some point with periodontal disease, treated or untreated.
- Patients with bruxism.
- Patients who are allergic to penicillin.

All patients were informed in detail about the objectives and procedures of the study, and they were given, in writing, an informed consent, which they had to accept to participate in the study.

Five hundred fifty-nine Zinic (Zicom Medical, S.L., Madrid, Spain) endosseous implants were used, with diameters of 3.7, 4.0, and 4.3 mm and lengths of 10 and 11.5 mm. All implants were titanium grade IV. The body displayed active coils with a reduced angle, double coil, transversal apical windows, and atraumatic tip. In addition, they presented an internal hexagonal connection, conical bevel and platform switch. All the implants used in the study shared the same surface treatment, thus the same macroporosity and microporosity. The only variations presented were length and diameter. All the implants were placed by the same operator.

The study was approved by Federico Henríquez y Carvajal University, Ethical Committee (Approval number: 10/2010), and written consents by the patients were obtained.

### Surgical Procedure

The surgical procedure used to insert the 559 implants included the following phases:

*First surgical phase (T0).* Corresponds to the insertion of the implant, with the

following guidelines being respected at all times:

- a. The surgical procedures were performed by the same operator.
- b. In cases where a tooth had to be extracted before implant insertion, we waited 3 months after the extraction before commencing the surgical procedure.
- c. Local, infiltrative anesthesia was used, and the chosen anesthetic was articaine with epinephrine with a concentration of 1:200,000.
- d. Using a no. 11 surgical blade, the supracrestal and paracrestal incisions were made (when the inserted gum was less than 2 mm from the median crest line to the mucogingival line), and the papilla of the tooth adjacent to the edentulous area was respected at all times, keeping a minimum distance of 1 mm.
- e. We then proceeded to perform the mucoperiosteal sweeping (total thickness) using a Molt periosteal elevator, and the surgical splints were positioned verifying stability and direction.
- f. The drilling sequence specified by the manufacturer was then used.
- g. All implants were inserted in the bone tissue in a contra angle with an insertion torque of at least 35 Ncm.
- h. The final implant insertion was performed manually with a ratchet wrench.
- i. We then proceeded to measure the RFA with the Osstell Mentor, taking 2 measurements: vestibular and lingual/palatine. To do this, we manually screwed a SmartPeg into the head of the implant requiring measurement. The tube was then inserted at a distance of 2 mm to the transducer, forming a 90-degree angle regarding the implant. The same Osstell Mentor was used for all measurements. To obtain the ISQ values, 2 different transducers were used to measure each implant. In order for the measurement to be considered valid, there could not be a variation of  $\pm 2$  units for each measurement between the 2 transducers—with the median being

- considered. The corresponding closing cap was put in place.
- j. The closing of the mucoperiosteal flap was performed with simple, double-knot stitches with 3/0 thread and 3/8 needle, triangular section, half curve, and reverse cut.
  - k. At the end of the surgery, each patient received 1 mL of betamethasone sodium phosphate/betamethasone acetate, in sterile aqueous suspension in an intramuscular manner, corresponding to 6 mg.
  - l. Participants were also treated with 875 mg of amoxicillin and 125 mg of clavulanic acid every 12 hours over the course of 5 days starting the day before the surgery and 600 mg of ibuprofen with arginine every 12 hours over the course of 3 days starting the day the implant was inserted. In cases of moderate to severe pain, the medication was supplemented with 575 mg of magnesium metamizole.
  - m. Patients were informed of the required techniques to maintain proper oral hygiene at the site of the surgery using a surgical toothbrush, as well as of the remaining teeth, and to apply chlorhexidine 0.2% gel every 8 hours for 10 days.
  - n. Stitches were removed 7 to 10 days after the implant was inserted.
  - o. During each intervention, note was taken of the number of implants inserted, the location, the diameter, the length, and the ISQ values obtained during the vestibular and lingual measurements of each implant.

*Second surgical phase after surgery (T1).* Corresponded to the reopening phase following the period of osseointegration (3 months after implant insertion), to remove the closing cap and to place the healing abutment. Local, infiltrative anesthesia was used, and the chosen anesthetic was articaine with epinephrine, with a concentration of 1:200,000.

Two surgical techniques were used, as per the clinical parameters in place:

- a. Flap surgery with no movement of tissue: When the level of inserted mucosa was between 2 and 5 mm, a supracrestal incision was made halfway through the width of the keratinized gingival band, perpendicular to the implant, and enabled the detachment of a vestibular and lingual/palatine mucoperiosteal flap, allowing access to the cover screw.
- b. Flap technique with apical repositioning: It was performed when the level of inserted mucosa was less than or equal to 2 mm. We followed the same principles as in the previous technique, but performing two, 1-mm vertical sweeps up to the mucogingival line.

In this second phase, the RFA was measured using the same device and following the same protocol as described in the surgical procedure.

ISQ values obtained when measuring the vestibular and lingual of each implant were taken. The healing abutment was inserted in accordance with the manufacturer's recommendations. The closing of the mucoperiosteal flaps was performed with simple, double-knot stitches with 3/0 thread and 3/8 needle, triangular section, half curve, and reverse cut. Patients were informed of the required techniques to maintain proper oral hygiene at the site of the surgery using a surgical toothbrush, as well as of the remaining teeth, and to apply chlorhexidine 0.2% gel every 8 hours for 10 days and take 600 mg of ibuprofen with arginine every 12 hours that same day.

*Prosthetic phase.* It was performed 14 to 16 days after the second surgical phase, using the open-tray technique for impression taking.

The prostheses used were partial or fixed, unique crowns in metal ceramic, and never more than 3 pieces. The crowns were cemented with provisional material.

*First control phase (T2).* It was performed 6 months after the surgical phase. The prosthetic rehabilitation was removed, and the ISQ values obtained previously were measured

once again following the same protocol as in the surgical phase. All results were compiled in the record and follow-up table.

*Second control phase (T3).* It was performed 1 year after the surgical phase. Prosthetic rehabilitations were removed, and the ISQ values obtained previously were measured once again following the same protocol as in the surgical phase. All results were compiled in the record and follow-up table.

#### Statistical Analysis

Comparisons between the various ISQ values were performed in accordance with the following criteria:

- Significance level 5% ( $\alpha$  value = 0.05)
- Comparison of median values performed after a 2-queue model, with no hypothesis: The average of the first group is equal to the average of the second group; alternative hypothesis: The average of the first group is not equal to the average of the second group.
- The most adequate method of comparison was the T test with 2 independent variables (based on the method of the t for Student), as the samples being compared were of different sizes and data numbers generally  $>40$ .
- The results of the comparisons were expressed in accordance with *P* value, as per the following values: If *P* value  $<0.05$  (significance level), the differences noted in the median values are considered significant (with a 95% trust level).

## RESULTS

A total of 195 patients were selected with ages ranging from 25 to 68 years (average age 47.5). A total of 559 implants were inserted: 45.97% in women and 54.03% in men, with the number of implants placed in men being significantly greater than in women (*P* value = 0.007  $<0.05$ ).

In this study, men's ISQ was 70.99  $\pm$  9.91 and women's was 69  $\pm$  11.70, a statistically significant difference (*P*-value = 0.000  $<0.05$ ). When

comparing results for diameter, we obtained statistically significant differences for the 3.7-mm diameter (with a value of  $70.48 \pm 9.80$  in men compared with  $68.47 \pm 10.87$  in women), and a  $P$  value = 0.001. The same applies for diameter 4.3 mm (with an ISQ median value of  $71.51 \pm 9.19$  in men compared with women at  $66.92 \pm 13.26$ ) and a  $P$  value = 0.000.

Of the 559 implants inserted, none failed. In total, 278 were inserted in the maxilla and 276 in the mandible. The number of implants placed in posterior sections was significantly greater than the number placed in anterior sections (206 posterior maxilla implants and 245 posterior mandible) ( $P$  value = 0.000). When analyzing the median ISQ values obtained, we observe that in the mandible, the value is of  $71.18 \pm 11.08$  compared with  $68.98 \pm 10.41$  for the maxilla, the difference being significant with a  $P$  value = 0.000.

When analyzing the diameters of the implants, we observe that, most frequently (325), the diameter is of 3.7 mm (more frequent in men), followed by 112 units with a diameter of 4.0 mm (more frequent in women) and 122 implants are of 4.3 mm (more frequent in men).

The average ISQ values regarding the diameters were of  $69.62 \pm$  for 3.7-mm implants,  $72.02 \pm$  for 4-mm implants and  $69.67 \pm$  for 4.3-mm implants.

If we consider ISQ values in relation to the diameters and measuring times (T0, T1, T2, and T3), we observe significant differences for the diameter of 4.0 mm in the T0, which obtained greater ISQ values than the other diameters. In T1, the relationship continues to be statistically significant for implants with a diameter of 4.0 mm and those with a diameter of 4.3 mm. For measurements taken at 6 months and 1 year, we did not observe statistically significant differences between any of the diameters (Fig. 1).

When breaking down these values for measurements taken for vestibular (V) and lingual/palatine (L), it can be observed that, in T0, the values obtained for V with a 4.0-mm diameter are significantly greater than for 3.7- and 4.3-mm implants. Conversely, the measurement for L was only significantly greater in 4.0 when compared with 4.3.

In T1, the L measurement maintains its higher value for the 4.0-mm diameter, when compared with the 4.3-mm L implant. In contrast to the previous results whereby a median for ISQ values was established, in T2 and T3, we can observe statistically significant differences between 4.0- and 3.7-mm diameters (with measurement for L in T2 and V in T3) (Fig. 2).

When analyzing the relationship between the diameter, implant site, and absolute ISQ times and values, one can observe a lack of significant difference in the T0. However, when breaking down the measurements for V and L, it becomes clear, and significantly so, that the values obtained in the anterior maxilla (lingual) for 4.0-mm implants versus 3.7-mm implants, differ (Fig. 3). In T1, we can also observe statistically significant differences when comparing absolute ISQ values between implants with 4.0-mm diameter located in the anterior maxilla and with those of the 3.7-mm variety, with the former having significantly greater values than the latter. This affirmation is also confirmed when breaking down the values obtained for vestibular and lingual for the same diameters (Fig. 4). At 6 months, T2, we can observe once again that the implants with 4.0-mm diameter present values greater than those with 3.7 and 4.3 mm, with these values being significant for posterior maxilla, again for vestibular and lingual. There is also a significant difference between the values of implants with 4.0-mm diameter for lingual, with greater value, compared with 4.3-mm diameter in posterior maxilla (Fig. 5). In the last measurement, in T3, we can observe once again that absolute ISQ values are significantly greater in the anterior maxilla for 4.0-mm implants than for 3.7 mm. When breaking down the ISQ values, we can observe that they become greater for 4.0-mm diameter (both vestibular and lingual), compared with 3.7 mm. This is also the case when we compare them with posterior maxilla, vestibular, 4.3 mm (Fig. 6).

## DISCUSSION

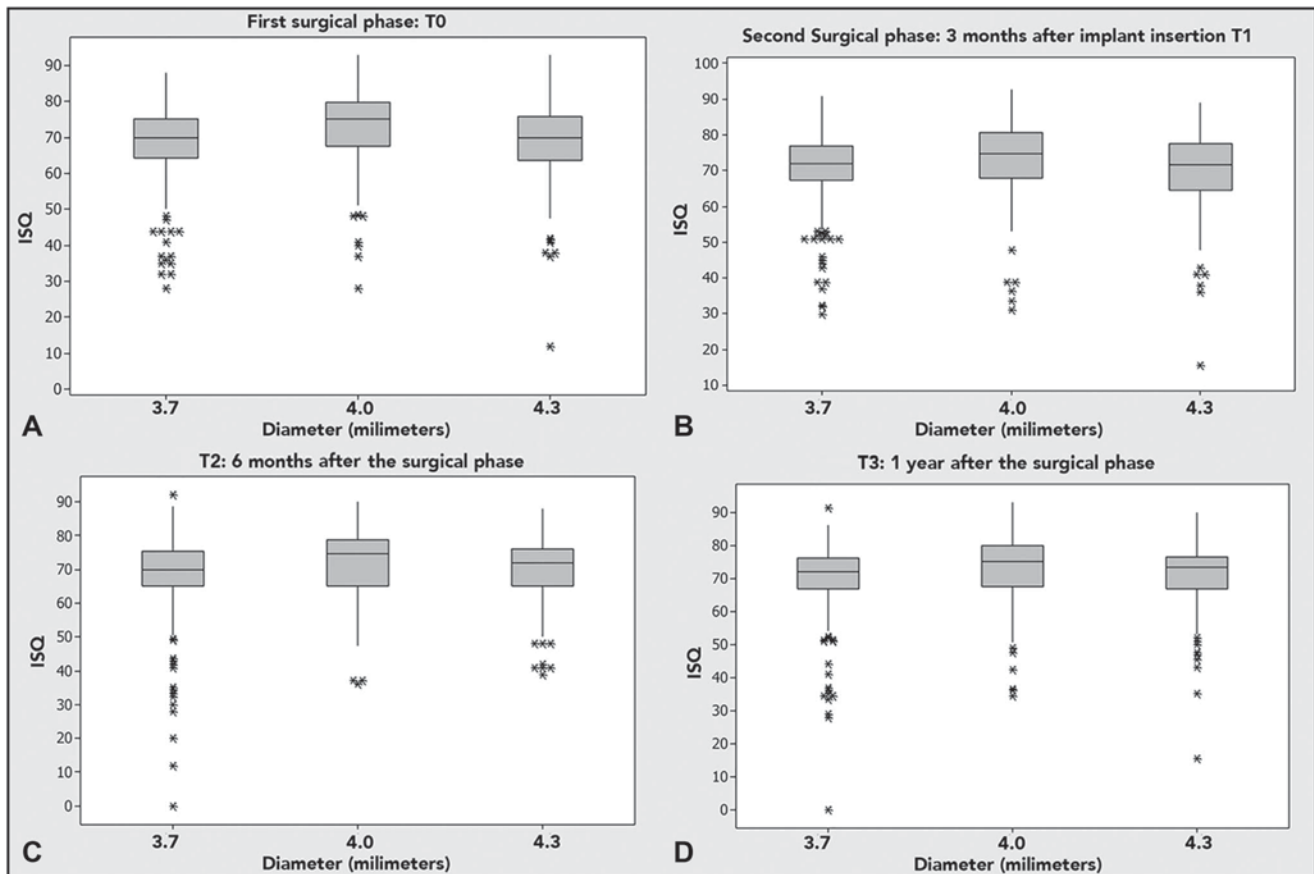
In the past years, many studies have focussed on discovering the factors that

influence proper implant stability, both primary and secondary. Said factors have been described as quantity, bone quality, surgical technique, and the geometry of the implants, its length and diameter.<sup>15,17-19</sup>

To objectify and obtain reproducible data, numerous studies have established that the RFA is of great use for measuring primary stability and evaluating possible implant prognosis in a noninvasive manner through ISQ values.<sup>12,16,20,29-34</sup>

In this study, we wished to verify whether implant diameter was at all linked to ISQ values, as well as to verify the relationship between diameter and other factors such as sex, implant site in the maxillaries, and surgical technique and procedure. In this article, while studying the ISQ values in relation to the diameter, we did not observe a link between a greater ISQ and a larger diameter. In fact, in T0, we observed significant differences between 4.0-mm implants with a value of  $71.96 \pm 11.35$ , significantly greater than the 3.7-mm implants with a result of  $68.64 \pm 10.11$  ( $P = 0.007$ ) and those with the largest, 4.3-mm diameter  $69.68 \pm 11.51$  ( $P = 0.041$ ). When comparing these results with the literature, we observed a certain degree of controversy and lack of unanimity, which could be due to crown size. In this study, 4.3-mm implants have the same shape and size as the 3.7 and 4.0 mm ones, although the diameter of the implant body increases for the 4.3. The fact that they are the same size may influence the stability coefficient: the difference between the bone part of the crown and the gap between the implant part of the crown, due to the use of the countersink.

There are reports of *in vitro* studies that use animal bones as substrate, like the study by Bilhan et al,<sup>16</sup> who, in 2010, placed ninety 3.8- and 4.6-mm implants and similarly, to this study, did not find statistically significant differences between the diameters and the ISQ values. This coincides with the results obtained by Ohta et al<sup>33</sup> in 2010, who performed a study on 3.5-, 4.3-, and 5-mm implants. These findings also coincide with the study on cadavers by Pommer et al<sup>34</sup> in 2012, who presented no evidence of a significant difference



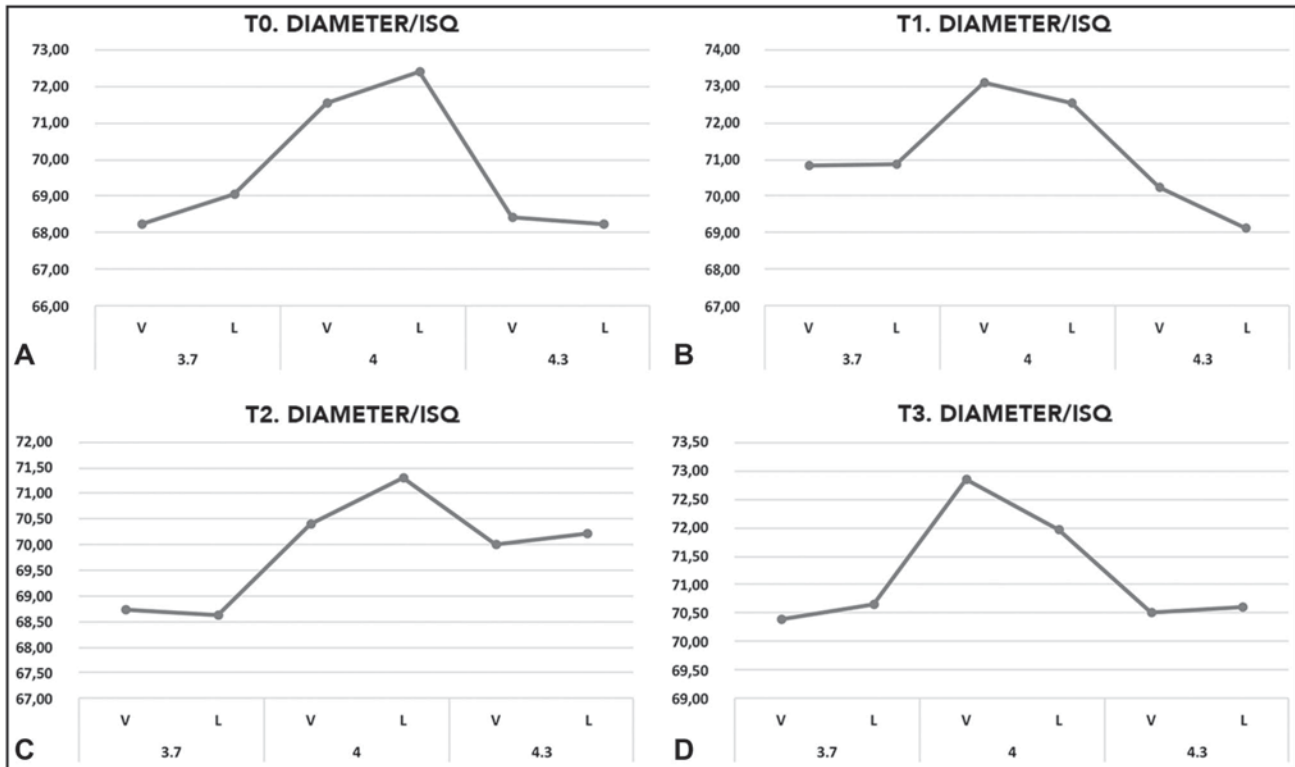
**Fig. 1.** **A**, T0. Diameter 3.7 versus 4.0 mm ( $P$  value = 0.007 < 0.05) and 4.0 versus 4.3 mm ( $P$  value = 0.019 < 0.05). **B**, T1. Diameter 4.0 versus 4.3 mm ( $P$  value = 0.041 < 0.05). **C** and **D**, In T2 and T3, there are no significant differences.\*Atypical cases.

between these 2 parameters. However, the studies did not maintain the same crown diameter. There have been other studies on artificial bone, with widely different results. Tözüm et al<sup>35</sup> affirm in 2008 that implants with a larger diameter obtain higher ISQ values (3.7 vs 4.8 mm), unlike this study which establishes that the 4.0-mm implant maintains the greatest stability coefficient. Barikani et al<sup>14</sup> revealed that implants with a narrow platform present significantly lower ISQ when compared with implants with regular and wide platforms. This differs from this study, which uses platforms of the exact same size, with the only variation being the diameter of the implant. In 2017, Hsu et al<sup>36</sup> only evidenced a significant increase in ISQ in implants with a 6-mm diameter. It is possible that the lack of unanimity among these studies is due to the fact they were performed on models and not *in vivo*.

If we analyze the published results of studies performed on living subjects with a view to understanding the possible relationship between ISQ values and implant diameter, we find that more than half of the studies reviewed have established a link between the high ISQ values and greater implant diameter. This is the case of Östman et al<sup>37</sup> who in 2006 performed a clinical trial on 905 implants with diameters of 3.75, 4, and 5 mm and found that the 5-mm implants had a significantly greater primary stability. These authors argue that wider implants tend to interlock more easily with the cortical layers and, for that reason, demonstrate greater primary stability. In 2010, Degidi et al<sup>12</sup> studied 4135 implants from the same implant system with diameters of 3.0, 3.4, 3.8, 4.5, and 5.5 mm. They found a small correlation between the high ISQ values and 5.5-mm diameter implants, with a median value of  $74.02 \pm 11.28$ , a figure

considerably higher than the average values obtained in this study, whereby the largest diameter is 4.3 mm. In 2012, the clinical trial of Rokn et al<sup>31</sup> placed 304 implants from 2 implants systems and varying diameters (3.3, 3.5, 4.1, 4.3, 4.8, and 5 mm), demonstrating that conical implants with greater diameter held higher ISQ values but did not specify the crown shape. In 2012, Park et al<sup>38</sup> performed an *in vivo* study with 2 different types of implants (a total of 41), establishing that the ISQ increased the larger the diameter of the implant, but did not reference the crown changes of the implants, nor if they maintained the same microtopography.

Guler et al<sup>39</sup> examined the ISQ values of 208 Straumann implants with diameters of 3.3, 4.1, and 4.8 mm. They obtained significant differences for the various implant diameters—at 4 weeks (ISQ 64.6) for implants with a 4.8-mm diameter and at 8 to 12 weeks, the



**Fig. 2.** **A**, T0. Diameter 4.0 V (71.53 ± 11.55) versus 4.3 mm V (68.41 ± 12.50) with  $P$  value = 0.049 < 0.05. In diameter 4.0 L (72.40 ± 11.57) versus 3.7 L (69.05 ± 10.49) with  $P$  value = 0.007 < 0.05. In diameter 4.0 L (72.40 ± 11.57) versus 4.3 L (68.25 ± 12.58) with  $P$  value = 0.009 < 0.05. **B**, T1 In diameter 4.0 L (72.55 ± 12.89) versus 4.3 L (69.13 ± 12.32) with  $P$  value = 0.039 < 0.05. **C**, T2 In diameter 4.0 L (71.31 ± 11.46) versus 3.7 L (68.20 ± 11.04) with  $P$  value = 0.032 < 0.05. **D**, T3 In diameter 4.0 V (72.85 ± 11.31) versus 3.7 V (70.39 ± 9.90) with  $P$  value = 0.043 < 0.05.

values for 4.1- and 4.8-mm implants were significantly greater than those for 3.3 mm, with an ISQ of 71.2 and 72.1, respectively.

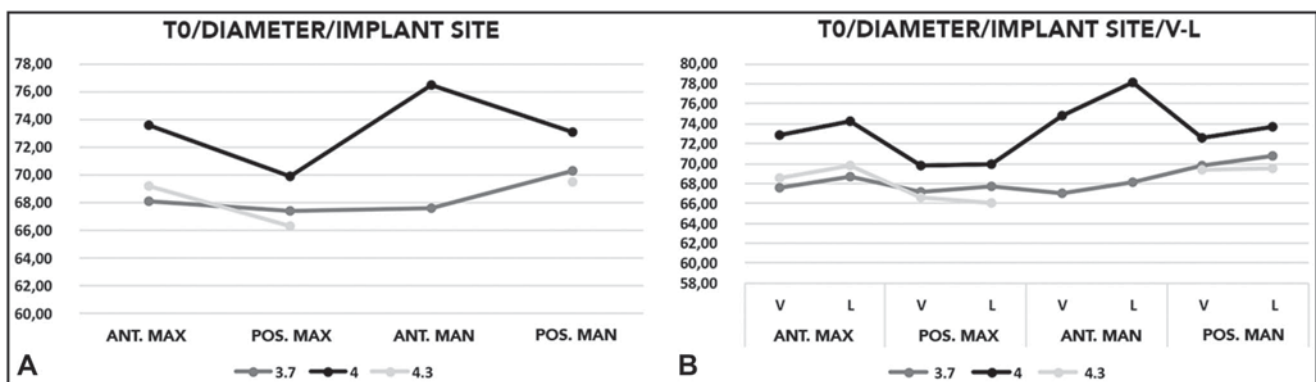
Much like this study, in 2014, Gehrke et al<sup>40</sup> studied 100 conical implants with diameters of 3.5 and 4 mm, and obtained a statistically significant

link between the RFA findings and the diameter (3.5 < 4 mm).

In 2016, Gultekin et al<sup>41</sup> performed a retrospective study on a total of 103 implants (from 2 different systems). The diameters varied from 3.8 to 4.6 mm. They demonstrated that the ISQ increased for implants with larger diameters (4.6 mm

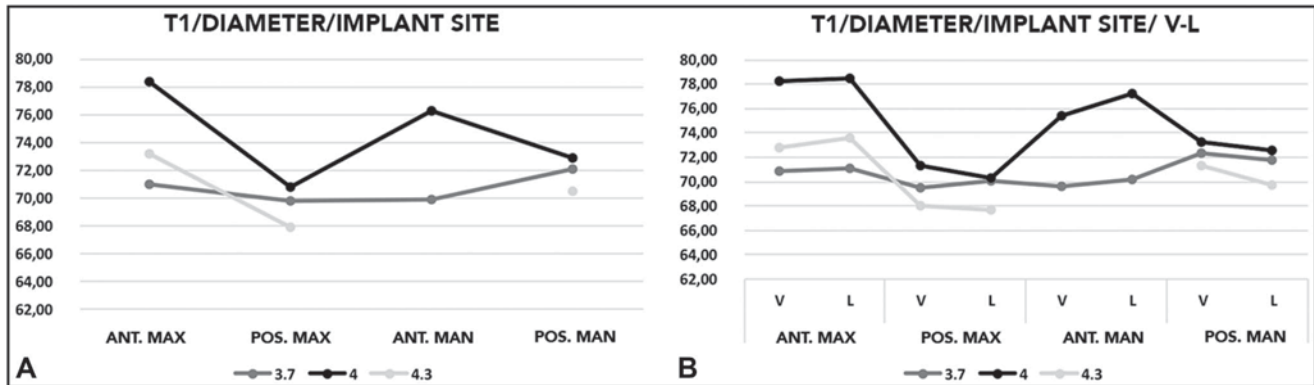
compared with 3.8 mm), both at 0 to 8 weeks and at 12 weeks. In this instance, the difference in diameter between the implants in both studies is almost double and crown shape changes as well.

The latest studies evaluated confirm a positive link between high ISQ values and a larger diameter. Such an



**Fig. 3.** **A**, No significant differences in absolute ISQ values. **B**, In anterior maxilla, diameter 4.0 L (74.23 ± 11.75) versus 3.7 L (68.65 ± 8.60) with  $P$  value = 0.034 < 0.05.





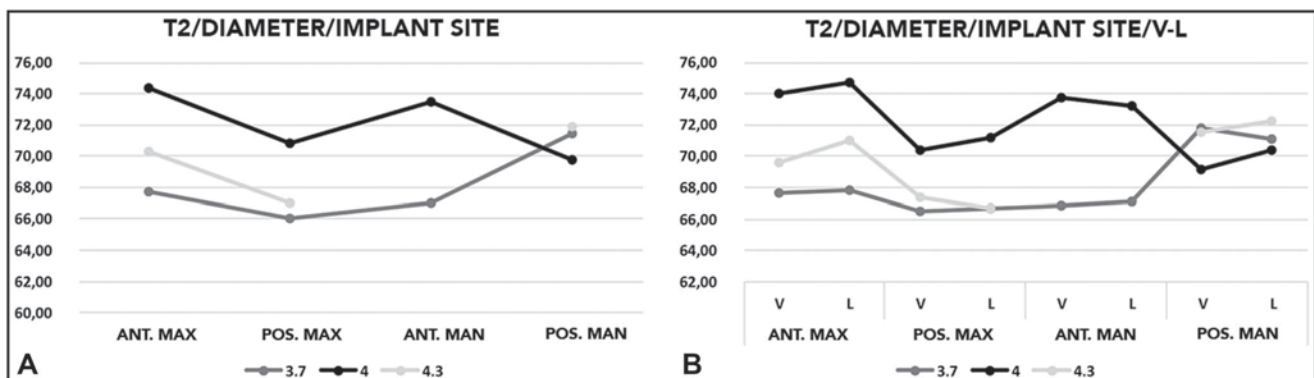
**Fig. 4. A,** T1. Anterior maxilla. In diameter 4.0 ( $78.38 \pm 9.81$ ) versus 3.7 ( $70.97 \pm 6.58$ ) with  $P$  value =  $0.021 < 0.05$ . **B,** T1. Anterior maxilla. In diameter 4.0 V ( $78.31 \pm 10.80$ ) versus 3.7 V ( $70.91 \pm 7.17$ ) with  $P$  value =  $0.034 < 0.05$  and for diameter 4.0 L ( $78.46 \pm 9.18$ ) versus 3.7 L ( $71.04 \pm 6.54$ ) with  $P$  value =  $0.015 < 0.05$ .

example is the work of Kim et al,<sup>42</sup> who, in 2017, used 573 implants from different systems and obtained significant values for implants  $< 5$  mm (ISQ  $78.33 \pm 7.12$ ) and those  $\geq 5$  mm (ISQ  $80.29 \pm 7.14$ ). Another example is that of Huang et al<sup>43</sup> in 2017, who studied the ISQ values obtained from 329 implants from different systems and demonstrated that the diameter of the implant was a significant influencing factor, but only when measuring the ISQ before the final restoration. They also concluded that the 1.5-mm diameter difference found in 3.5- and 5-mm implants could result in a difference of 5.175 to 6.296 in ISQ values, without evaluating the changes in crown platform.

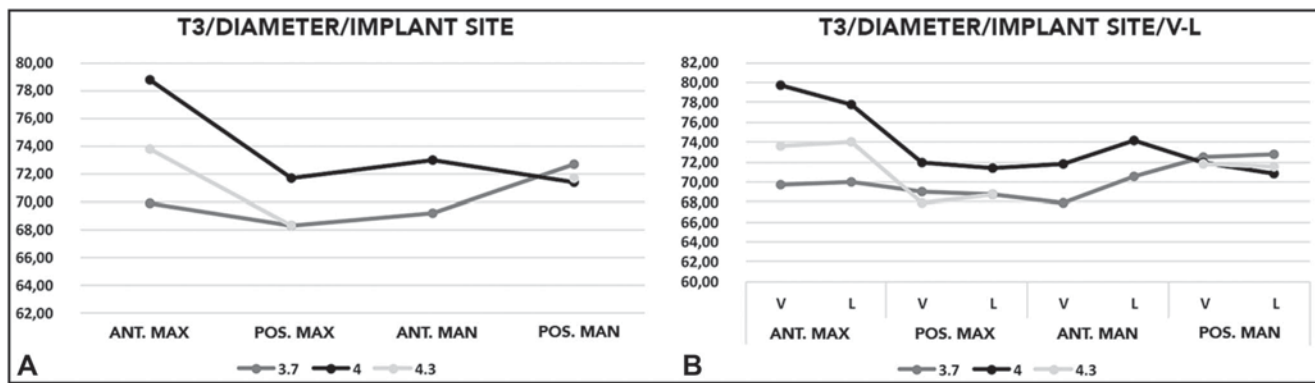
Conversely, there are works that argue that there is no direct and

significant link between higher ISQ values and a larger implant diameter. Such is the case of Bischof et al,<sup>19</sup> who, in 2004, studied 106 implants, or Huwiler et al,<sup>22</sup> who, in 2007, studied 17 implants of 4.1 and 4.8 mm and measured at the time of surgery and after at weeks 1, 2, 3, 4, 5, 6, 8, and 12, coinciding with Han et al,<sup>44</sup> who, in 2019, performed a prospective clinical study on 25 implants of the same diameter and performing the same controls. There were no links found in the work of Merheb et al<sup>45</sup> in 2010 either, who studied 3.3- and 4.1-mm implants in a sample totaling 136, or in the study of González-García et al<sup>32</sup> in 2011, who concluded in a study on 68 implants from a single system that the diameter of the implant (3.75 and 4.25 mm) did not have a significant effect on the ISQ values.

With respect to the ISQ values measured in this study, during the surgery (T0), the link with the diameters was of  $68.64 \pm 11.11$  for 3.7-mm implants,  $71.96 \pm 11.35$  for 4-mm implants, and  $68.33 \pm 12.2$  for 4.3-mm implants. Inferior results compared with those obtained by González-García et al,<sup>33</sup> who obtained a median value for implants of 3.75 mm of  $78.4 \pm 5.46$  and of  $80.83 \pm 5.35$  for implants of 4.25 mm. However, the results obtained in this study are greater than those obtained by Guler et al,<sup>39</sup> whose values were  $62.78 \pm 6.95$  for 3.3-mm implants,  $65.07 \pm 8.19$  for 4.1-mm implants, and  $65.54 \pm 8.71$  for 4.8-mm implants. The same goes for data obtained by Degidi et al<sup>12</sup> in 2010:  $70.32 \pm 11.63$  for 3.0-mm implants,  $71.59 \pm 10.03$  for 3.4-mm implants,



**Fig. 5. A,** T2. Posterior maxilla. In diameter 4.0 mm ( $70.82 \pm 8.97$ ) versus 3.7 mm ( $66.03 \pm 12.26$ ) with  $P$  value =  $0.007 < 0.05$  and diameter 4.0 versus 4.3 mm ( $67.01 \pm 8.59$ ) with  $P$  value =  $0.044 < 0.05$ . **B,** T2. Posterior maxilla. In diameter 4.0 V ( $70.41 \pm 8.97$ ) versus 3.7 V ( $66.48 \pm 11.15$ ) with  $P$  value =  $0.021 < 0.05$ . In diameter 4.0 L ( $71.22 \pm 9.33$ ) versus 3.7 L ( $66.69 \pm 10.87$ ) with  $P$  value =  $0.009 < 0.05$ . In diameter 4.0 L ( $71.22 \pm 9.33$ ) versus 4.3 L ( $66.65 \pm 9.28$ ) with  $P$  value =  $0.023 < 0.05$ .



**Fig. 6. A**, T3. Anterior maxilla. In diameter 4.0 ( $78.73 \pm 10.41$ ) versus 3.7 ( $69.85 \pm 10.11$ ) with  $P$  value =  $0.013 < 0.05$ . **B**, T3. Anterior maxilla. In diameter 4.0 V ( $79.69 \pm 9.55$ ) versus 3.7 V ( $69.69 \pm 9.79$ ) with  $P$  value =  $0.003 < 0.05$ . In diameter 4.0 L ( $77.77 \pm 11.82$ ) versus 3.7 L ( $70.02 \pm 10.71$ ) with  $P$  value =  $0.046 < 0.05$ . Posterior maxilla. In diameter 4.0 V ( $72.00 \pm 9.09$ ) versus 4.3 V ( $67.84 \pm 9.06$ ) with  $P$  value =  $0.033 < 0.05$ .

$71.15 \pm 10.47$  for 3.8-mm implants,  $71.94 \pm 11.29$  for 4.5-mm implants, and  $74.02 \pm 11.28$  for 5.5-mm implants. These differences could be attributed to the surgical protocol or the crown countersink.

In the second surgical phase, the results were of  $70.84 \pm 9.5$  for 3.7-mm implants,  $72.41 \pm 11.85$  for 4-mm implants, and  $69.68 \pm 11.51$  for 4.3-mm implants. These figures are still way below those obtained by González-García et al,<sup>32</sup> who observed greater values in the second surgical phase than in the first surgical phase, the opposite of this study:  $76.68 \pm 4.34$  for 3.75-mm implants and of  $78.22 \pm 6.87$  for 4.25-mm implants. In this study, ISQ values increase over a period of 3 months for the diameters studied. Guler et al<sup>39</sup> also demonstrate a fairly considerable increase in ISQ values during the second phase of their study ( $67.74 \pm 6.31$  for 3.3-mm implants,  $71.20 \pm 5.58$  for 4.1-mm implants and  $72.12 \pm 6.50$  for 4.8-mm implants), although not all ISQ evaluations were performed at 12 weeks. Some of their implants were checked at 8 weeks; perhaps, this caused the data to vary as much as it did.

Regarding the potential differences between the sexes, some authors consider that ISQ values are greater for men than for women. After analyzing 905 implants, Östman et al<sup>37</sup> concluded that the average ISQ for men is 68.5, whereas for women, it is 66.5. Kim et al<sup>42</sup> establish the difference to be  $79.78 \pm 6.82$  for men versus  $78.34 \pm 7.63$  for women.

Guler et al<sup>39</sup> only found significant differences between the sexes at 4 weeks, which coincides with this study, positing that the average ISQ for men was greater than that for women. Furthermore, when analyzing the difference for diameter, we can conclude that for 3.7 mm and for 4.3 mm, the difference is statistically significant in favor of men. However, there are no studies that perform these comparisons.

Other authors such as Rognk et al<sup>31</sup> consider that there are no differences in ISQ between the sexes, having studied a total of 304 implants from 2 different systems, coinciding with the results obtained by González-García et al.<sup>32</sup>

When studying the relationship between ISQ values and implant diameter and site placement in the maxillaries, no works have analyzed the ISQ values obtained in measurements for vestibular and lingual.

Generally speaking, and much the same as in this study, multiple authors establish that, for the mandible, ISQ values are greater than for the maxilla, and they all argue that this is due to a difference in bone density which is why values for the mandible are greater than for the maxilla, with a statistically significant difference for diameters 3.7 and 4.3 mm. These results coincide with the literature reviewed.<sup>20,38-41</sup>

When analyzing the measuring times in this study, there are no significant differences observed in T0 as far as absolute ISQ values are concerned. However, in the disaggregated values,

a significant difference is observed ( $P$  value =  $0.034 < 0.05$ ) in the anterior maxilla and in palatine when comparing diameters 4.0 ( $74.23 \pm 11.75$ ) and 3.7 ( $68.65 \pm 8.60$ ) mm. This discrepancy could be due to the fact that, during the surgical phase, the countersink hole was 4.0 mm in diameter, meaning that 3.75-mm implants bore a discrepancy of 0.25 mm. Conversely, for 4.0-mm implants, crown stability was perfect. This discrepancy, in addition to a finer vestibular cortical layer, may have produced the difference. These values are superior to those obtained in the study by Bischof et al,<sup>19</sup> who studied 106 implants from the same manufacturer and concluded that for 4.1-mm implants, values ranged from 55.4 to 60.5 (maxilla and mandible, respectively) and for 4.8 mm from 53 to 57 (maxilla vs mandible). This significant difference in the absolute ISQ values could be due to, as argued by Snijders et al<sup>29</sup> in 2013, measurements being taken with different generations of Osstell, with Osstell Mentor values being greater.

In T1, there is a clearly greater ISQ value for 4-mm implants ( $78.38 \pm 9.81$ ) in comparison with 3.7-mm implants ( $70.97 \pm 6.58$ ) and only in the anterior maxillary area. These values increase that much more when referring to ISQ values for vestibular and lingual, with vestibular obtaining values of  $78.31 \pm 10.80$  and lingual of  $78.46 \pm 9.18$  for 4.0-mm implants compared with values of  $70.91 \pm 7.17$  for vestibular and  $71.04 \pm 6.54$  for lingual for 3.7-mm implants,

with both comparisons presenting significant differences. The reason could also be due to the fact that bone in these areas is more sponge-like, and the larger diameter would improve the bone-implant contact in the crown area, which presents the majority of cortical. It could also be due to crown adjustments during surgery or loss of crestal bone stemming from imperfect countersink adjustment in 3.7-mm implants. This affirmation is confirmed for 4.3-mm implants, with an average ISQ value of  $73.2 \pm 6.26$  as previously mentioned. The crown countersink is 4.0 mm in diameter, a perfect fit for implants of that size. When a 4.3-mm implant passes through the crown area, the countersink shifts and creates a gap of +0.3 mm between the implant and the bone part of the crown. In this second period, there are also discrepancies regarding the results obtained by Bischof et al,<sup>19</sup> who affirmed that for 4.1-mm implants, values obtained ranged from 57.1 to 64.7 (maxilla and mandible, respectively) and for 4.8 mm from 56.7 to 61.6 (maxilla vs mandible). These results, despite rising similarly to this study, are nevertheless still quite low.

In T2, we evidence a significant difference in the maxilla, both in absolute and disaggregate ISQ values, although in this case we are referring to the posterior area, where values for 4.0-mm implants ( $70.82 \pm 8.97$ ) are greater and of statistical significance when compared with 3.7-mm implants ( $66.03 \pm 12.26$ ). The same occurs when comparing 4.0-mm implants with 4.3-mm implants ( $67.01 \pm 8.59$ ), which could be due to a lack of adjustment or cortical crown loss with the implant—which is why they do not change over time.

At the year mark in T3, we obtain statistically significant values in the anterior maxillary area when comparing the results for 4-mm implants ( $78.73 \pm 10.41$ ) with those for 3.7-mm implants ( $69.85 \pm 10.11$ ). In the disaggregate values, we observe the same results for vestibular and lingual, with a clear difference in the values obtained in vestibular for the posterior maxilla for 4.0- and 4.3-mm implants. This could be due to crestal bone loss as a result of a lack of crown adjustment.

In 2012, Park et al<sup>38</sup> analyzed the ISQ values of 81 implants but did not break down the values as we have in this study. Nevertheless, and as opposed to these results, they did not establish a link between the ISQ value and the anterior-posterior positioning of the implants. Conversely, Östman et al<sup>37</sup> obtained higher ISQ values in posterior sections.

## CONCLUSIONS

In this study on patients who are partially edentulous, the RFA measured at the time of endosseous implant insertion and at 3, 6, and 12 months, thereafter, showed that, as far as diameter is concerned, there is no link between greater ISQ values and larger implant diameters. However, 4.0-mm implants returned greater RFA values possibly due to implant bed preparation in the crown area.

As for the possible variations concerning sex, this study established that men's ISQ values are greater than women's. In addition, when relating back to diameter, we observed significant differences for 3.7- and 4.3-mm diameters.

Regarding placement site, the results obtained coincide with the literature, and we can confirm that the greatest ISQ values are located in the mandible. What is more, when relating back to diameter, we observed significant differences for 3.7- and 4.3-mm diameters.

## DISCLOSURE

The authors claim to have no financial interest, either directly or indirectly, in the products or information listed in the article.

## APPROVAL

This study was approved by Federico Henriquez y Carvajal University, Faculty of Dentistry Ethical Committee (approval #10/2010), and written consents by the patients were obtained.

## ROLES/CONTRIBUTIONS BY AUTHORS

J. M. Aragoneses: Substantial contributions to the conception or design of the work, revising the work critically for important intellectual content, final

approval of the version to be published, agreement to be accountable for all aspects of the work in ensuring that questions related to the accuracy, or integrity of any part of the work are appropriately investigated and resolved. A. Suárez: Substantial contributions to the analysis and interpretation of data for the work; drafting or revising the work. V. A. Brugal: served as scientific advisor. M. Gómez served as scientific advisor.

## ACKNOWLEDGMENTS

All figures were performed by Angel Sánchez. Angel Sánchez: data analysis and interpretation.

## REFERENCES

- Esposito M, Grusovin MG, Achille H, et al. Interventions for replacing missing teeth: Different times for loading dental implants. *Cochrane Database Syst Rev*. 2009;CD003878.
- Lioubavina-Hack N, Lang NP, Karring T. Significance of primary stability for osseointegration of dental implants. *Clin Oral Implants Res*. 2006;17:244-250.
- Sennerby L, Roos J. Surgical determinants of clinical success of osseointegrated oral implants: A review of the literature. *Int J Prosthodont*. 1998;11:408-420.
- O'Sullivan D, Sennerby L, Meredith N. Influence of implant taper on the primary and secondary stability of osseointegrated titanium implants. *Clin Oral Implants Res*. 2004;15:474-480.
- Akkocaoglu M, Uysal S, Tekdemir I, et al. Implant design and intraosseous stability of immediately placed implants: A human cadaver study. *Clin Oral Implants Res*. 2005;16:202-209.
- Sevimay M, Turhan F, Kiliçarslan MA, et al. Three-dimensional finite element analysis of the effect of different bone quality on stress distribution in an implant-supported crown. *J Prosthet Dent*. 2005;93:227-234.
- Berglundh T, Abrahamsson I, Lang NP, et al. De novo alveolar bone formation adjacent to endosseous implants. *Clin Oral Implants Res*. 2003;14:251-262.
- Oates TW, Valderrama P, Bischof M, et al. Enhanced implant stability with a chemically modified SLA surface: A randomized pilot study. *Int J Oral Maxillofac Impl*. 2007;22:755-760.
- Herrero-Climent M, Albertini M, Rios-Santos JV, et al. Resonance frequency analysis-reliability in third generation instruments: Osstell mentor. *Med Oral Patol Oral Cir Bucal*. 2012;17:e801-6.

10. Meredith N, Alleyne D, Cawley P. Quantitative determination of the stability of the implant-tissue interface using resonance frequency analysis. *Clin Oral Implants Res.* 1996;7:261-267.
11. Meredith N, Shagaldi F, Alleyne D, et al. The application of resonance frequency measurements to study the stability of titanium implants during healing in the rabbit tibia. *Clin Oral Implants Res.* 1997;8:234-243.
12. Degidi M, Daprile G, Piattelli A. Primary stability determination by means of insertion torque and RFA in a sample of 4,135 implants. *Clin Oral Implants Res.* 2012;14:501-507.
13. Barikani H, Rashtak S, Akbari S, et al. The effect of shape, length and diameter of implants on primary stability based on resonance frequency analysis. *Dent Res J.* 2014;11:87-91.
14. Barikani H, Rashtak S, Akbari S, et al. The effect of implant length and diameter on the primary stability in different bone types. *J Dent (Tehran).* 2013;10:449-455.
15. Sennerby L, Meredith N. Implant stability measurements using resonance frequency analysis: Biological and biomechanical aspects and clinical implications. *Periodontol 2000.* 2008;47:51-66.
16. Bilhan H, Geckili O, Mumcu E, et al. Influence of surgical technique, implant shape and diameter on the primary stability in cancellous bone. *J Oral Rehabil.* 2010;37:900-907.
17. Alghamdi H, Anand PS, Anil S. Under-sized implant site preparation to enhance primary implant stability in poor bone density: A prospective clinical study. *J Oral Maxillofac Surg.* 2011;69:E506-E512.
18. Turkyilmaz I. A comparison between insertion torque and resonance frequency in the assessment of torque capacity and primary stability of Brånemark system implants. *J Oral Rehabil.* 2006;33:754-759.
19. Bischof M, Nedir R, Szmukler-Moncler S, et al. Implant stability measurement of delayed and immediately loaded implants during healing. *Clin Oral Implants Res.* 2004;15:529-539.
20. Zix J, Kessler-Liechti G, Mericske-Stern R. Stability measurements of 1-stage implants in the maxilla by means of resonance frequency analysis: A pilot study. *Int J Oral Maxillofac Implants.* 2005;20:747-752.
21. Kessler-Liechti G, Zix J, Mericske-Stern R. Stability measurements of 1-stage implants in the edentulous mandible by means of resonance frequency analysis. *Int J Oral Maxillofac Implants.* 2008;23:353-358.
22. Huwiler MA, Pjetursson BE, Bosshardt DD, et al. Resonance frequency analysis in relation to jawbone characteristics and during early healing of implant installation. *Clin Oral Implants Res.* 2007;18:275-280.
23. Nedir R, Bischof M, Szmukler-Moncler S, et al. Predicting osseointegration by means of implant primary stability. *Clin Oral Implants Res.* 2004;15:520-528.
24. Glauser R, Sennerby L, Meredith N, et al. Resonance frequency analysis of implants subjected to immediate or early functional occlusal loading. Successful vs. failing implants. *Clin Oral Implants Res.* 2004;15:428-434.
25. Becker W, Sennerby L, Bedrossian E, et al. Implant stability measurements for implants placed at the time of extraction: A cohort, prospective clinical trial. *J Periodontol.* 2005;76:391-397.
26. Rodrigo D, Aracil L, Martin C, et al. Resonance frequency analysis of implants subjected to immediate or early functional occlusal loading. Successful vs. failing implants. *Clin Oral Implants Res.* 2010;21:255-261.
27. Queiroz TP, Aguiar SC, Margonar R, et al. Clinical study on survival rate of short implants placed in the posterior mandibular region: Resonance frequency analysis. *Clin Oral Implants Res.* 2015;26:1036-1042.
28. Jaramillo R, Santos R, Lázaro P, et al. Comparative analysis of 2 resonance frequency measurement devices: Osstell Mentor and Osstell ISQ. *Implant Dent.* 2014;23:351-356.
29. Sniijders RS, van Wijk AJ, Lindeboom JA, et al. A comparative study of the Osstell versus the Osstell Mentor to evaluate implant stability in human cadaver mandibles. *J Oral Rehabil.* 2013;40:774-779.
30. Lages FS, Douglas-de Oliveira DW, Costa FO. Relationship between implant stability measurements obtained by insertion torque and resonance frequency analysis: A systematic review. *Clin Implant Dent Relat Res.* 2018;20:26-33.
31. Rokn A, Ghahroudi AR, Mesgarzadeh A, et al. Evaluation of stability changes in tapered and parallel wall implants: A human clinical trial. *J Dent (Tehran).* 2011;8:186-200.
32. González-García R, Monje F, Moreno-García C. Predictability of the resonance frequency analysis in the survival of dental implants placed in the anterior non-atrophied edentulous mandible. *Med Oral Patol Oral Cir Bucal.* 2011;16:e664-9.
33. Ohta K, Takechi M, Minami M, et al. Influence of factors related to implant stability detected by wireless resonance frequency analysis device. *J Oral Rehabil.* 2010;37:131-137.
34. Pommer B, Hof M, Fädler A, et al. Primary implant stability in the atrophic sinus floor of human cadaver maxillae: Impact of residual ridge height, bone density, and implant diameter. *Clin Oral Implants Res.* 2014;25:e109-13.
35. Tözüm TF, Turkyilmaz I, McGlumphy EA. Relationship between dental implant stability determined by resonance frequency analysis measurements and peri-implant vertical defects: An in vitro study. *J Oral Rehabil.* 2008;35:739-744.
36. Hsu JT, Shen YW, Kuo CW, et al. Impacts of 3D bone-to-implant contact and implant diameter on primary stability of dental implant. *J Formos Med Assoc.* 2017;116:582-590.
37. Östman PO, Hellman M, Wendelhag I, et al. Resonance frequency analysis measurements of implants at placement surgery. *Int J Prosthodont.* 2006;19:77-83.
38. Park KJ, Kwon JY, Kim SK, et al. The relationship between implant stability quotient values and implant insertion variables: A clinical study. *J Oral Rehabil.* 2012;39:151-159.
39. Guler AU, Sumer M, Duran I, et al. Resonance frequency analysis of 208 Straumann dental implants during the healing period. *J Oral Implantol.* 2013;39:161-167.
40. Gehrke SA, Tavares da Silva Neto U. Does the time of osseointegration in the maxilla and mandible differ?. *J Craniofac Surg.* 2014;25:2117-2120.
41. Gultekin BA, Sıralı A, Gultekin P, et al. Clinical evaluation of the stability of implants placed at different supracrestal levels. *J Istanbul Univ Fac Dent.* 2016;50:21-31.
42. Kim YH, Choi NR, Kim YD. The factors that influence postoperative stability of the dental implants in posterior edentulous maxilla. *Maxillofac Plast Reconstr Surg.* 2017;39:2.
43. Huang H, Xu Z, Shao X, et al. Multivariate linear regression analysis to identify general factors for quantitative predictions of implant stability quotient values. *PLoS One.* 2017;12:e0187010.
44. Han J, Lulic M, Lang NP. Factors influencing resonance frequency analysis assessed by Osstell mentor during implant tissue integration: II. Implant surface modifications and implant diameter. *Clin Oral Implants Res.* 2010;21:605-611.
45. Merheb J, Van Assche N, Coucke W, et al. Relationship between cortical bone thickness or computerized tomography-derived bone density values and implant stability. *Clin Oral Implants Res.* 2010;21:612-617.





Date: February 2019

Page: 150-155 N° 229

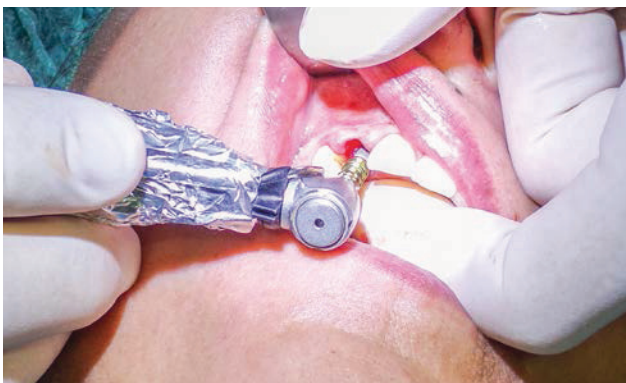
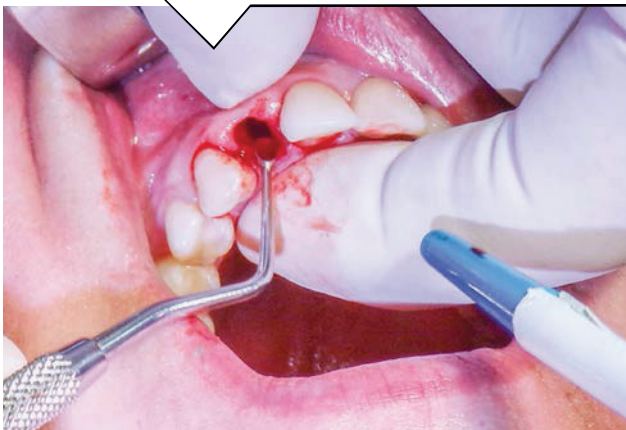
Country: Spain

Article name: IMMEDIATE LOADING ON ANTERIOR  
SINGLE IMMEDIATE IMPLANT.

Products: Zinic®

Dentist: Dr. Juan Pedro Mazón Esteve

# Immediate loading on anterior single immediate implant. A case report



**Dr. Juan Pedro Mazón Esteve**

Dentist by the European University of Valencia (UEV).  
Master in Advanced Oral Implantology by UEV.  
Professor of the Advanced Oral Implantology Master at UEV.

Valencia.

# science and practice

## Preamble

Immediate implantology is a prosthetic-surgical restoration technique of great clinical and scientific interest, as evidenced by the fact that among the 300 most cited articles in dental implantology publications, we can find in fifth place an article of immediate loading<sup>1</sup>. This interest seems to be consolidated with a greater total number of publications on this sub-discipline of implantology and an increase in research production focused on immediate implantology<sup>2</sup>.

The first report of successful immediate placement of ceramic implants after tooth extraction is made by Professor Wilfried Schulte<sup>3</sup>, although the clinical practice of immediate implantology is already described by Jourdain and Maggiollo in their

manual in 1807, where it is described, from empiricism and observation, the reabsorption of the post-extraction socket, as well as the partial end of the process when placing an implant, providing, in addition, a careful atraumatic extraction technique to preserve the alveolus and recommending the load of the crown a month after placement<sup>4</sup>.

Currently, the advantages of immediate implantology are several: less morbidity, fewer interventions and the possibility of an aesthetic provisionalisation when immediate loading is carried out in the anterior sector. An adequate indication and selection of the case is always recommended<sup>5</sup>.

The aesthetic parameters described by Kois JC (2001)<sup>6</sup> help us to make an adequate prognosis of the peri-implant aesthetic result before performing the extraction. According to Buser et al. (2017), the cases indicated for this type of treatment would represent only 5-10% of the single teeth to be extracted in the aesthetic zone<sup>7</sup>.

Therefore, rigorous selection criteria must be applied and it is recommended to have experience in the practice of implantology before dealing with this type of cases, as it is a categorised treatment of advanced difficulty<sup>8</sup>.



**Clinical case**

A patient attends the consultation referred by her dentist due to an unrestorable coronary fracture of tooth 12 (figs. 1 and 2). The patient was reluctant to place a conventional prosthesis, so it was decided, after conventional clinical and radiological examination and CBCT, the placement of a Zinic® implant (Ziacom®), 3.3 x 11.5 mm, post-extraction and the fabrication of a composite crown as an immediate aesthetic provisionalisation.

When performing the occlusion evaluation, an insufficient canine guide is observed, which will force the fabrication of a slightly shorter provisional crown, in order to avoid lateral loads that could lead to failure of the restoration (fig.3).

The atraumatic extraction and a meticulous alveolar curettage are performed (fig.4).

After checking that the alveolar sides have been preserved, "palatal corrected" drilling is carried out for an ideal 3D position of the implant (fig.5).

The procedure is evaluated intra-surgically with a periapical radiography (fig.6).

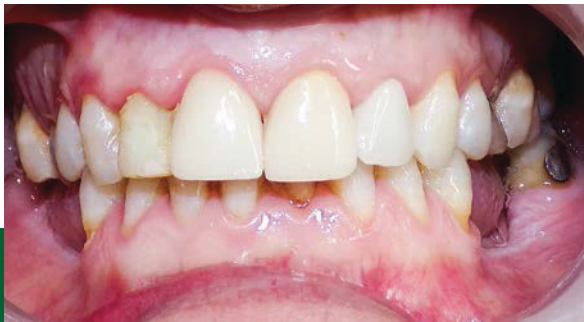

Fig. 1. Intraoral

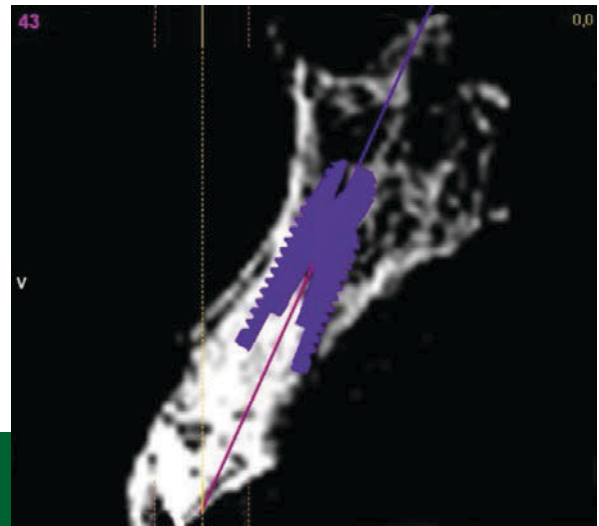


Fig. 2. Planning view with

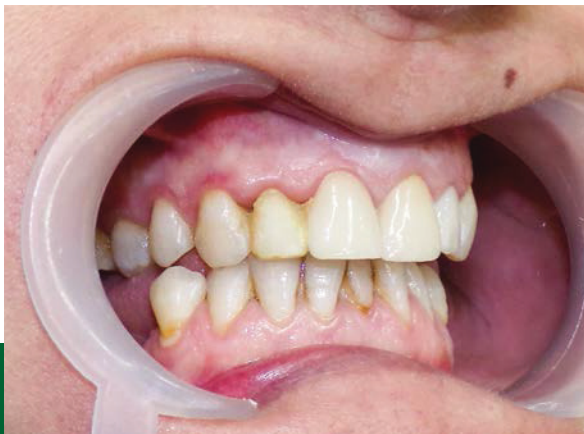

Fig. 3. Pattern

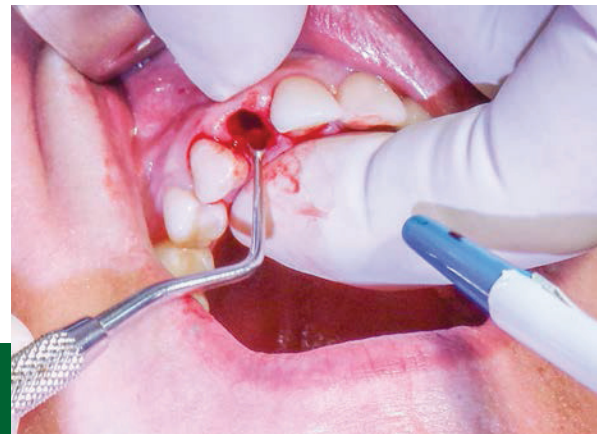

Fig. 4.

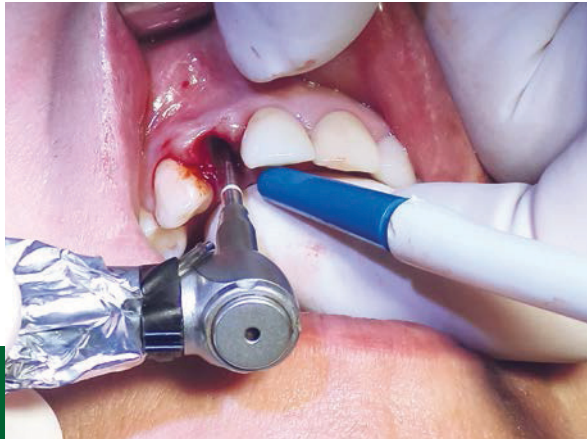
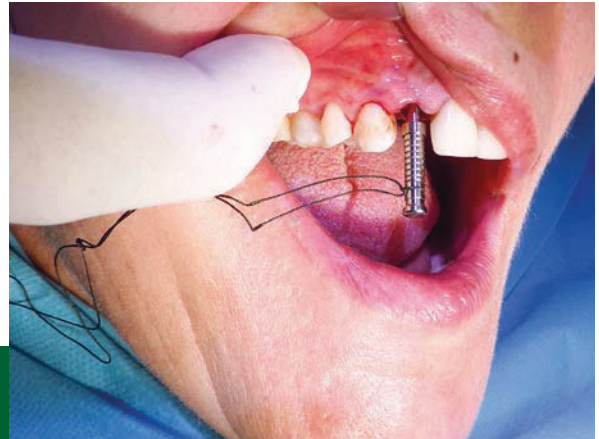
Fig. 5. Milling.



Parallel pin/depth gauge attached to a dental floss for safety reasons, to perform a control X-ray.

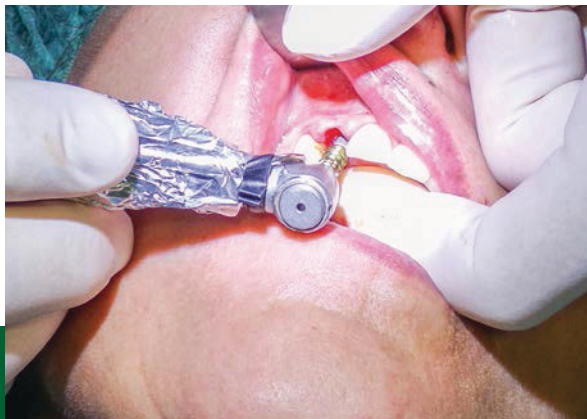

Fig. 7. Implant placement.

Implant placement is performed (fig.7). The primary stability achieved will be decisive when it concerns immediate aesthetic treatment that does not compromise the osseointegration of the implant (fig. 8). It is necessary to check the accurate fit of the implant mount used in the fabrication of the provisional abutment (fig. 9).

Successive controls will be carried out to assess the good evolution, after which the final crown will be made (figs.10 to 12).

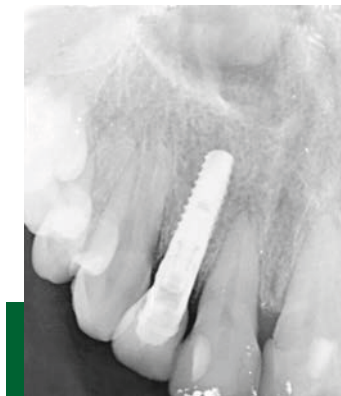

Fig. 9. Control fit X-ray

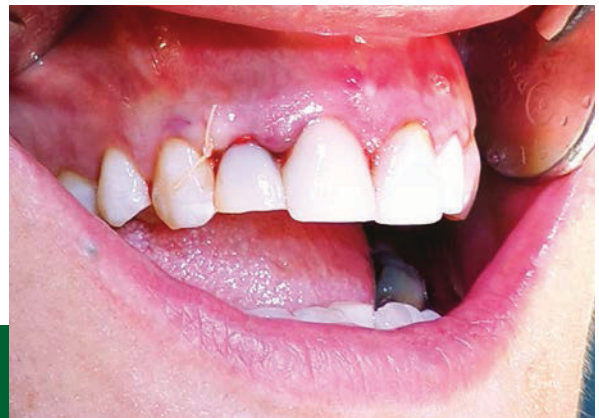

Fig. 8. Immediate.

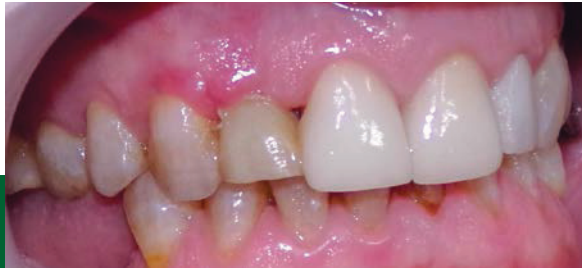

Fig. 10. Post-operative at three weeks.

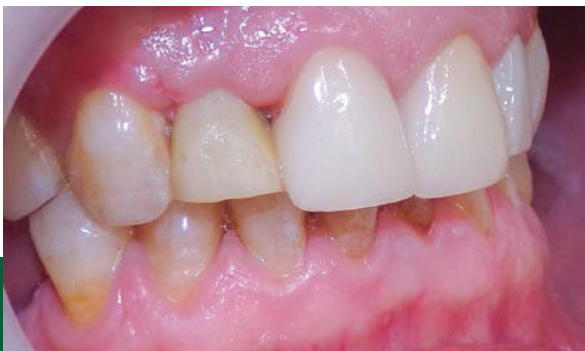

Fig. 11. Post-op after eight weeks.

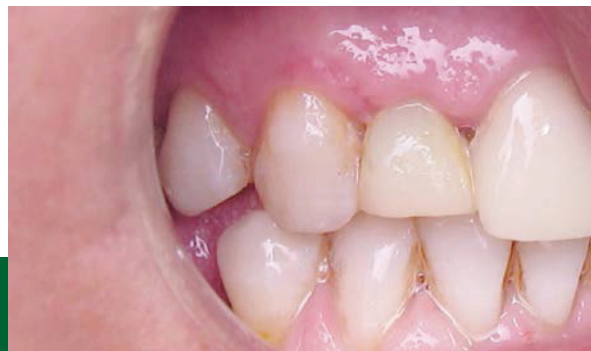

Fig. 12. Postoperative after three months.

## Conclusions

A correct selection of the case and a meticulous surgical management, with an adequate selection of the materials, allow to carry out an immediate implantology that reduces the surgical times and increases the patient's satisfaction with the received treatment.

## Bibliography

- 1 Alarcón M, Esparza D, Montoya C, Monje A, Faggion C. The 300 Most-cited articles in implant dentistry. The International Journal of Oral & Maxillofacial Implants. 2017; 32: e1-8. doi: 10.11607/jomi.5104.
- 2 Pommer B, Valkova V, Ubaidha Maheen C, Fürhauser L, Rausch-Fan X, Seeman R. Scientific interests of 21st century clinical oral implant research: topical trend analysis. Clinical Implant Dentistry and Related Research. 2016; 18: 850-6. doi:10.1111/cid.12371.
- 3 Schulte W, Kleinekenscheidt H, Lindner K, Schareyka R. The Tübingen immediate implant in clinical studies. Deutsche Zahnärztliche Zeitschrift. 1978; 33 (5): 348-859. Jourdain A, Maggiolo J. Le manuel de l'art du dentiste.
- 4 Tonetti MS, Cortellini P, Graziani F, Cairo F, Lang NP, Abundo R, Conforti GP, Marquardt S, Rasperini G, Silvestri M, Wallkamm B, Wetzel A. Immediate versus delayed implant placement after anterior single tooth extraction: the timing randomised controlled clinical trial. J Clin Periodontol 2017; 44: 215-224.
- 5 Kois JC. Predictable single tooth peri-implant esthetics: five diagnostic keys. Compend Contin Educ Dent 2001 Mar; 22 (3): 199-206; quiz 208.
- 6 Buser D, Chappuis V, Belser UC, Chen S. Implant placement post extraction in esthetic single tooth sites: when immediate, when early, when late? Periodontology 2000. 2017; 73 (1), 84-102.
- 7 Dawson A, Chen S, Buser D, Cordaro L, Martin W, Belser U. The SAC classification in implant dentistry. Quintessen Verlag. 2010.

# Dentistry

Date: 10 January 2019

Page: 42-43

Country: UK

Article name: ACHIEVING LONG-TERM SUCCESS WITH  
IMMEDIATE IMPLANT LOADING AND CONICAL  
CONNECTION

Products: GALAXY®

Dentist: Dr. Víctor Cubillo Blasco

# Achieving long-term success with immediate implant loading and conical connection

**Victor Cubillo Blasco** presents a case where a post-extraction conical connection implant was immediately placed and loaded following extraction

**Dr Victor Cubillo Blasco**  
Implant dentist

Nowadays everyone is focused on immediate results, and aesthetic results in particular.

To achieve these, implant dentists rely on a number of techniques. We place immediately-loaded implants,

perform bone and soft tissue grafts, use non-metal crowns, or turn to digital workflows, for example. Many dentists are still concerned about functionality and so use semi-adjustable or fully-adjustable articulators in order to control the occlusion, eccentric movements, or TMJ stability.

Some of us are also concerned about the long-term durability of the treatment – the real measure of success.

In order to achieve this final goal, we must not only be aware of all the above, but also consider the products we use, and how they affect the surrounding tissues in the short, medium and long term.

The benefits of the conical connection have been well-described in scientific literature. The Zicom Galaxy implant puts these benefits in your hands. The design of this implant means that chewing and biting forces are spread through the whole body of the implant and passed to the bone through a bigger BIC (bone to implant contact) area. Because of the conical connection, platform switching is possible. This will allow bone to 'grow' over the implant and soft tissue to achieve a stronger biological seal. The narrower the abutment over the implant, the stronger the biological seal will be.

Of course, we must remember that as we use Galaxy implants, the drilling sequences and the level we leave the implant are not the same as when using an implant with an internal hexagon connection. Every different connection – indeed, every different implant design – has its own workflow and, in order to achieve real success with our treatments, we must be familiar with them.

### Case study

In the case study pictured here, the patient presented with a fractured incisor. The loss of this tooth would have

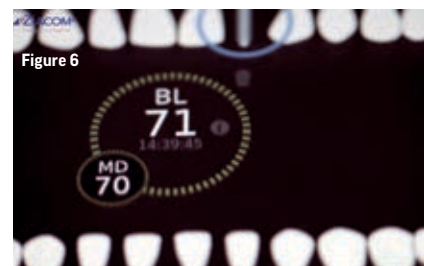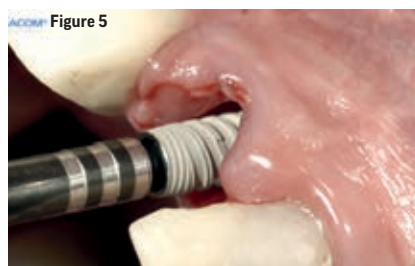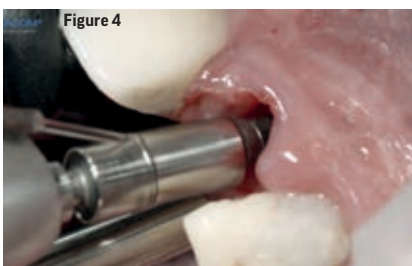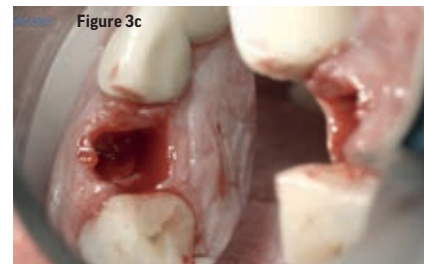
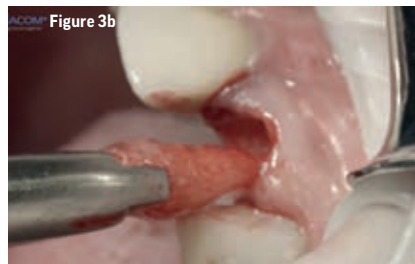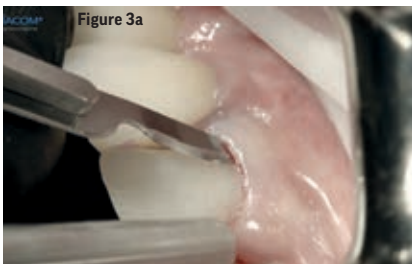
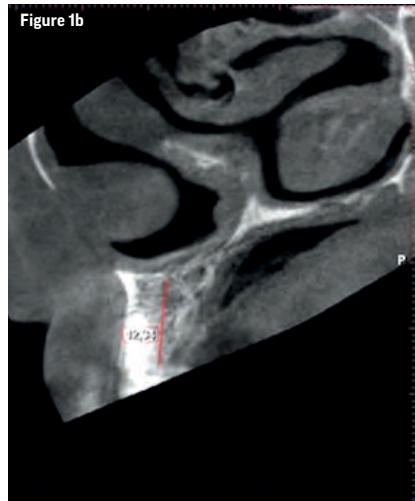


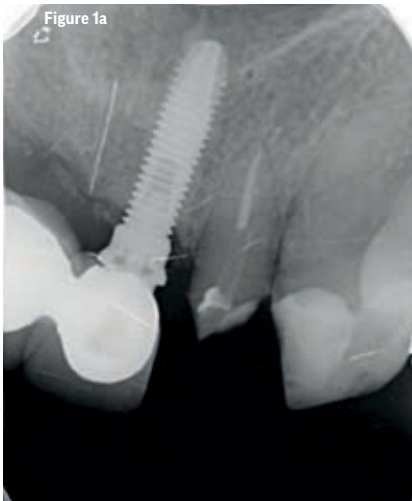Figure 7

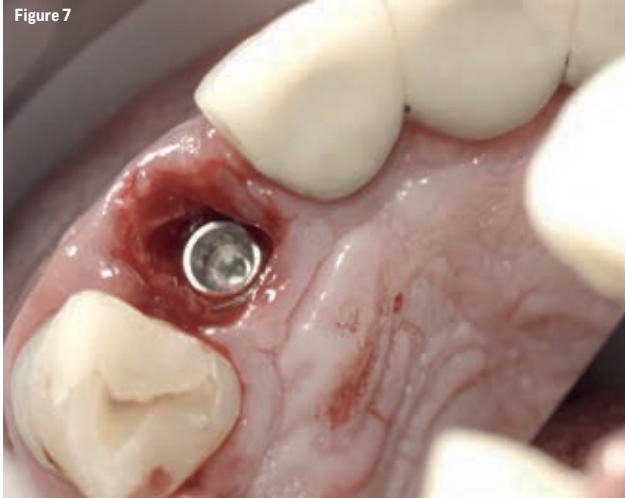
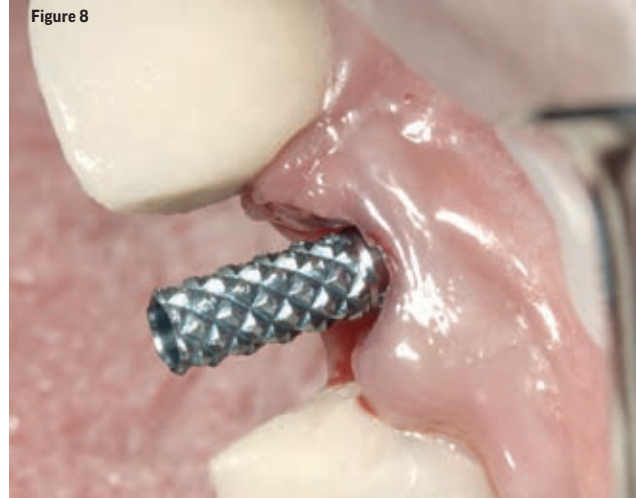
Figure 8



a great impact on the patient's life. Although it would have been possible to extract the affected tooth and wait for the recovery of the tissues, post-extraction implants and immediate load are considered the best possible solution to avoid early loss of the buccal plate and the papilla.

### Treatment options

Considering the only solution for the UL1 was extraction, the patient was presented with three possible treatments:

- 1. Removable prosthesis placement** – the only advantage of this option is its economy. It would not fit the patient's need for comfort. Furthermore, it would not prevent alveolar bone resorption and would require future surgical interventions to preserve both bone and soft tissues
- 2. Preparing adjacent teeth (UL1 and UL3) for placement of a ceramic bridge** – preparing and placing a ceramic bridge would have met the patient's requirements. That said, clinically, it would not prevent bone resorption nor gingival recession in the long term. In order to correct these issues, future interventions and new ceramic prostheses would be required
- 3. Implant placement to replace UL2** – the placement of an intraosseous implant insertion was the most aesthetic and functional option in both the short and long term. For favourable cases – like this one – the best option would be post-extraction implant placement and provisional immediate loading. This procedure would require the bone grafting of the alveolar gap, but in this way aesthetics, bone volume and gingival anatomy would all be preserved. Preserving interdental papilla at the front area is key to achieving natural aesthetics in such cases.

After discussing every option and complication with the patient, she chose the third option: implant placement.

### Treatment

- 1.** Radiographic evaluation of the patient
- 2.** We decided to place a Ziacom Galaxy implant, as it offers a great primary stability for these cases, thanks to the tapered and compressive design of its body. Due to the conical connection, it offers the perfect stability for hard tissues in the long term, and the platform switching would help soft and hard tissues over time
- 3.** The periodontal ligament was removed using a 15c scalpel shade. Atraumatic extraction of the tooth was carried out, aiming to cause as little damage as possible to the soft and hard tissues
- 4.** After cleaning the socket carefully, an osteotomy was carried out at the correct location. The ideal three-dimensional position would be for the implant axis to come up the palatal area; for this specific case, the axis of the implant would stay inside the limits of the correct area. This would allow a cemented or screwed ceramic restoration
- 5.** The implant was placed 1.5mm subcrestally to compensate for bone resorption when placing a post-extraction implant, and allow an extra 1mm because of the conical connection

**ZIACOM®**  
Making future together

Visit us at:



2 - 4 May 2019

Stand 23

EICC, Edinburgh



www.ziacom.co.uk

For more information please call to +44 129 332 40 13  
and book your appointment with one of our local Sales Representatives

Ziacom Medical UK Ltd - Tallis House - 2 Tallis Street - London, EC4Y 0AB - UK - Tel: +44 129 332 40 13 - info@ziacom.co.uk

6. Primary stability of the implant was checked using Osstell, which gave us an ISQ value of 71 – the right value at which to perform immediate loading
7. After the Galaxy implant was placed, its correct 3D position was checked
8. A provisional titanium abutment was then placed. This abutment was drilled and adjusted to receive a provisional composite crown. We used a PMMA tooth to elaborate the provisional crown while pasting it to the provisional titanium abutment with VisiLink adhesive and fluid composite, Crea-Lign (A1 colour). Once outside the mouth, we shaped the gingival emergence with fluid composite, before finally carefully polishing the crown
9. The healing abutment was placed to prevent the Ziacom Osseobone grafting biomaterial (made of beta tri-phosphate calcium) from getting inside the implant while grafting the gap. Bone regeneration of the socket-implant gap helps prevent bone resorption of the socket, preserving gingival stability.
10. The provisional crown was placed, screwed and splinted to the UL2 to manage greater stability.

### Summary

Immediate load post-extraction implants have been widely described in the literature.

Striving to perform these treatments in as flapless a fashion as possible makes a great difference to the final result.

The buccal plate is supplied with blood by the buccal

periosteum and by the alveolar artery. Since the alveolar artery is no longer available after the tooth extraction, preserving the buccal periosteum intact becomes a key factor.

Careful choice, not only of the type of implant to be used and its correct 3D position, but also the right prosthetic abutment and material, is vital for the long-term survival of the implant.

The amount of bone loss in post-extraction implants has also been well described in literature. To compensate this bone loss, the implant must be placed 1.5mm below bone level. Using the Galaxy implant, with its conical connection, will add at least 1mm to the implant placement. The implant overall will therefore be 2.5mm-3mm below bone level, ending up at 1.5mm below following average bone loss after extraction. This will require a 3mm abutment to give the soft tissue enough space to mature properly and allow a strong biological sealing.

The biological seal, along with the sub-bone level of the Galaxy implant and the effect of the conical connection force distribution and lack of micro movement, will greatly improve the long-term durability of the implant and the hard and soft tissues surrounding it and so the aesthetics and functionality.

From the surgical perspective, we have then done as much as we need to. From this point on, dentists' and technicians' ability to achieve an aesthetic prosthesis will have also a great impact on the final result. Contact points, emergence profiles and occlusal forces are all factors to

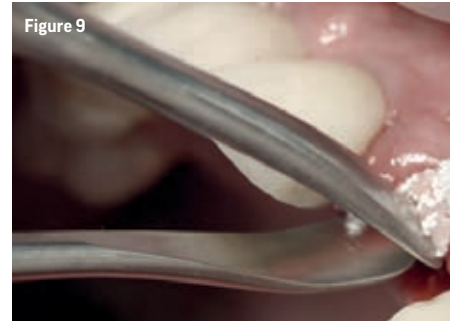

Figure 9

be seriously considered when designing and making the provisional crown in order to prepare and modify the soft tissue around the implant.

Today, clinicians must not only be concerned about the immediate result, but also with long term results. Implant treatments should replace a natural tooth as effectively and for as long as possible, which means the clinician must use the best available products in the correct way. Only then we can hope to imitate nature for the long term and talk about successful treatment. **D**

For a full list of references included with this article, email [julian@dentistry.co.uk](mailto:julian@dentistry.co.uk).

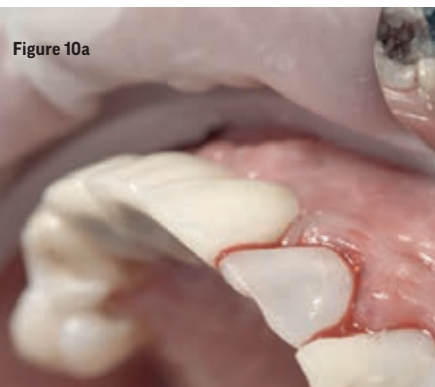

Figure 10a

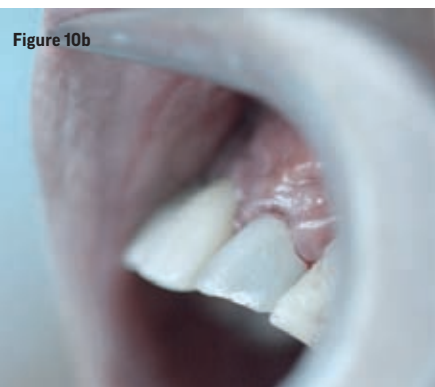

Figure 10b

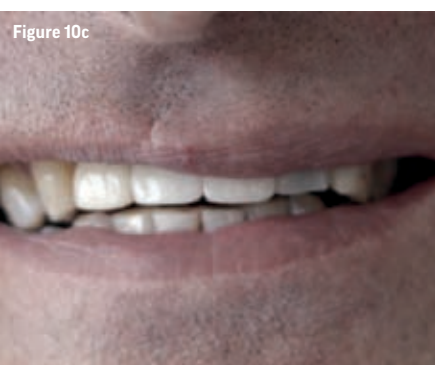

Figure 10c

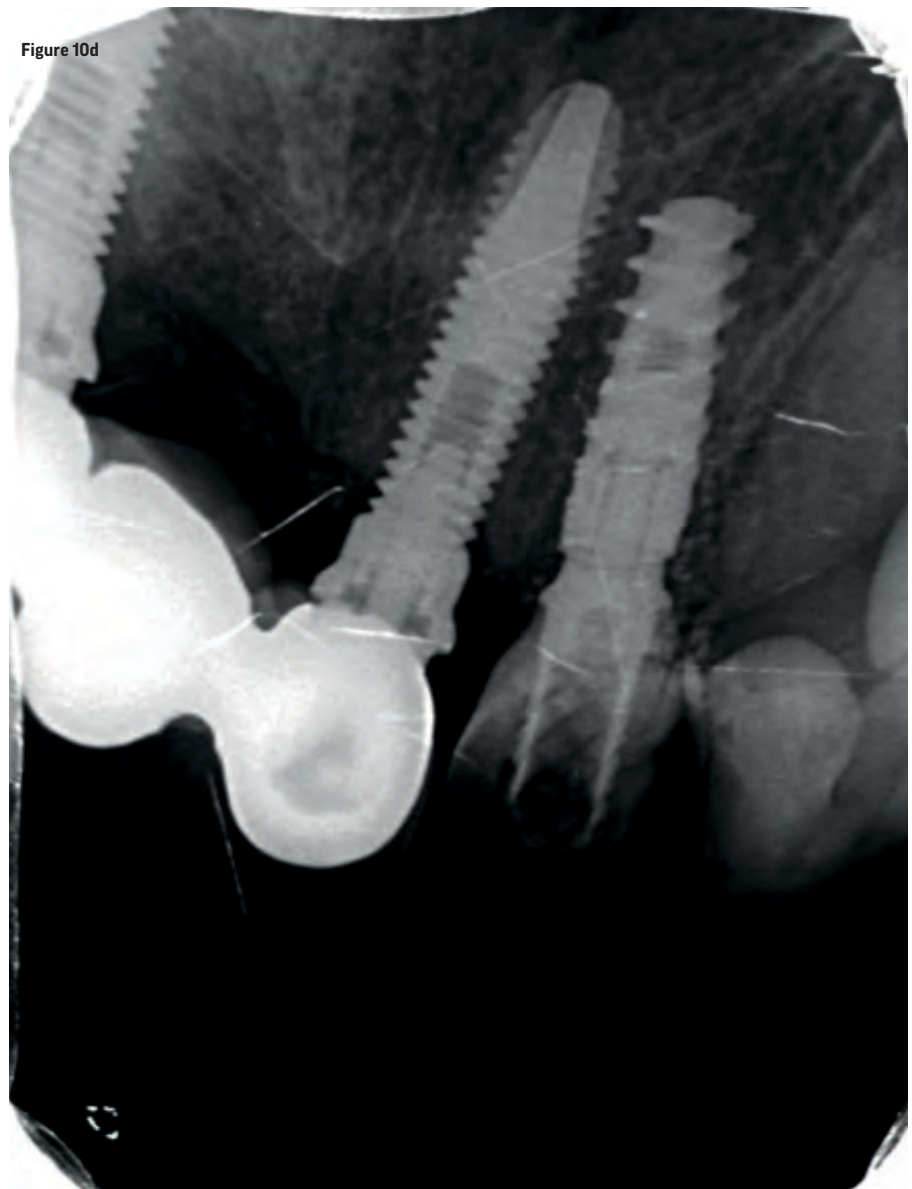


Figure 10d



**MaXILLARIS**

Date: December 2018

Page: 82 N° 224

Country: Spain

Article name: CONICAL BODY WITH REDUCED ANGLE  
DOUBLE THREAD AND ATRAUMATIC APEX.

Products: Zinic®MT and Ziacam® Ti-Base

Dentist: Dr. Víctor Cubillo Blasco





**ZINIC<sup>®</sup>MT**

**Manufacturer**

Ziacom Medical S.L.

**Distributor in Spain**

Ziacom Medical (own network).

**Market introduction year**

2004 (Spain).

**Shape**

Conical body with reduced angle double thread and atraumatic apex.

**Prosthetic connection type**

Compatible internal hexagon.

**Core material type**

Zitium<sup>®</sup>: high-pressure grade 4 titanium.

**Surface material type**

Osseonova<sup>®</sup>: sandblasting and double etching.

**Available lengths**

8,5 -10 - 11, 5 - 13 mm.

**Available diameters**

3,6 - 4 - 4,4 - 4,8 mm.

**Osseointegration period**

From 6 to 8 weeks.

**Cases in which immediate loading is accepted**

High primary stability (ISQ > 70).

**Long-term scientific studies**

Available.

**Prosthetic abutments type**

Prosthetic solutions: provisional abutments (PEEK or titanium), definitive abutments for cemented and screwed restorations, transepithelial abutments, overdentures abutments and CAD/CAM Ti-bases.

**Guarantee type**

Lifetime guarantee on dental implants.

**Additional information**

ZPlus<sup>®</sup> multifunction abutment: implant mount, impression transfer or provisional abutment for cemented-screwed restorations. Scanbodies are available for CAD-CAM prosthetic design. ZIACOR<sup>®</sup> CAD-CAM Service.

Kiran<sup>®</sup> clinical screw: high performance with surface treatment that reduces the risk of screw loosening.

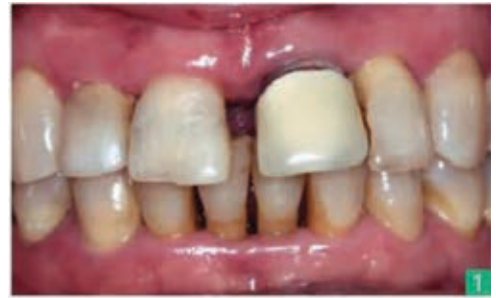Tx30<sup>®</sup> variable rotation abutment: for the correction of implants with unfavourable angulation.

Zinic<sup>®</sup>3D: Surgical planning software for guided surgery.

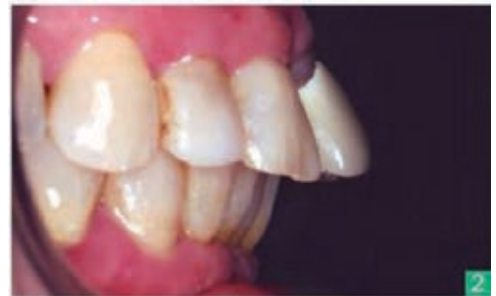Single restoration in aesthetic upper region.

Courtesy photos by Dr. Victor Cubillo Blasco (Tenerife, Spain).

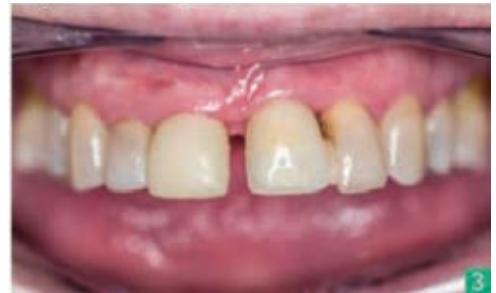Initial front view



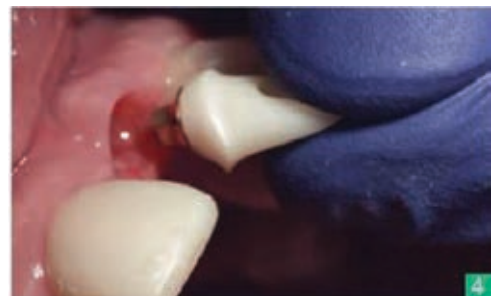Lateral initial view



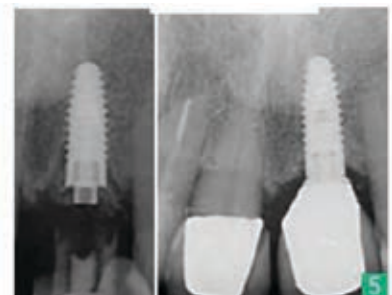
Immediate load with PEEK provisional abutment



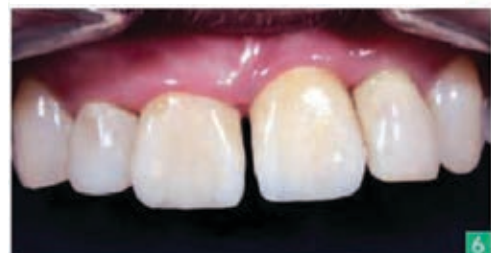Personalised zirconium abutment placement on TiBase Ziacom<sup>®</sup>



Control X-ray of the provisional and final restorations



Final restoration



# Dentistry

Date: 6 December 2018

Page: 23-24

Country: UK

Article name: POST-EXTRACTION AND IMMEDIATE  
LOADING FOR SOCKET PRESERVATION

Products: Zinic<sup>®</sup>MT

Dentist: Dr. Víctor Cubillo Blasco

# Post-extraction and immediate loading for socket preservation

**Victor Cubillo Blasco** presents an immediate loading case study using the PET technique

**Dr Victor Cubillo Blasco**

Implant dentist and odontologist

## Introduction

Dental implants have shown to be the best alternative to a natural tooth. The predictability, durability, aesthetics, comfort and functionality achieved are far better than with any other treatment option to replace a natural missing tooth. There are hundreds of implants to choose from, made from different materials, with many different designs, connections, surface treatments, prosthetic abutments.

Until few years ago, it was enough to follow the correct surgical technique, so the implant would be placed

## And from the professional point of view, immediate loading has shown to be at least as effective as deferred loading

correctly to support the prostheses. But then immediate loading turned out to be essential to patients. Patients did not want just implants to replace missing teeth, they wanted aesthetics too. To have a gap in the denture for few months was no longer acceptable. And from the professional point of view, immediate loading has shown to be at least as effective as deferred loading. Not only the

aesthetics regarding the dental gap, but also the soft tissue and bone support are improved with immediate loading implants, especially post-extraction.

The next goal to be achieved was to sustain the initial results over time, so different techniques for socket preservation were described as surgeons realised the bone that once held the roots would eventually be lost.

To graft the socket with different biomaterials is the only solution to prevent bone loss and therefore a change in aesthetics and to compromise long term durability.

One of the newest techniques described for socket preservation is partial extraction therapy (PET) or socket shield. This technique is based on preserving the blood flow to the vestibular plate. If we preserve vascularisation to the vestibular bone plate, it will not be lost and with the bone volume preserved it will support the gum volume.

## Case

A male patient – 47 years old – with no medical issues, was referred to our dental clinic with toothache on the UR4. Only after a CBVT, a vertical fracture line from mesial to distal was discovered. The tooth had no fillings and no decay. During the clinical examination, clear signs of bruxism were detected.

## Options

Every possible treatment is explained to the patient including:

- Tooth extraction, and placing a removable denture
- Tooth extraction, and drilling UR3 and UR5 to prepare a dental-fixed ceramic bridge
- Tooth extraction, wait 16 weeks for healing and then placing an intraosseous implant, whether immediate loading or not, along with some socket

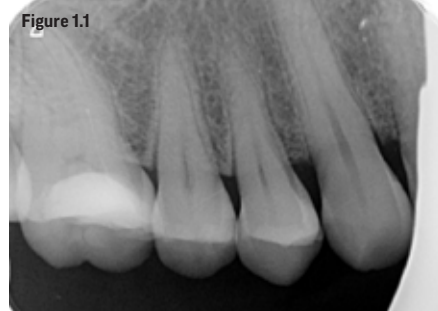

Figure 1.1

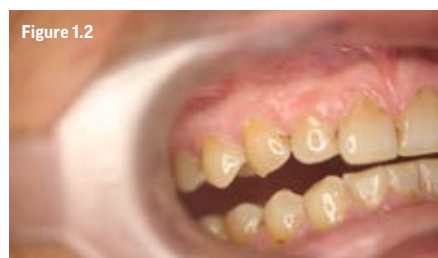


Figure 1.2

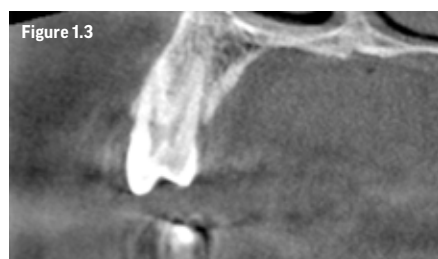

Figure 1.3

Offer valid until 12/21/2018

**ZIACOM®**  
Making future together

Visit us at:

**Implant  
Dentistry  
Show**

26th January 2019

Stand 47

Novotel London West

**60 implants + 2 Surgical Boxes  
+ Trip to Madrid (to visit our facilities)**


Voucher Code: 60MADRID2018\*

Only

**£6,000**

VAT excluded

Offer is valid until the end of December 2018



**Zinic<sup>MT</sup>**



**ZIACOM®**  
Making future together



www.ziacom.co.uk

\* Voucher Code: 60MADRID2018

Offer is valid until the end of December 2018.

Call to +44 129 332 4013 for more info, book your appointment with local sales reps and use your voucher.

Offer is not available in conjunction with any other promotions.

Ziacom Medical UK Ltd - Tallis House - 2 Tallis Street - London, EC4Y 0AB - UK - Tel: +44 129 332 40 13 - sales@ziacom.co.uk

preservation procedures

- D.** Tooth extraction, placing an intraosseous implant with PET and immediate load a crown.

Along with every possible treatment, every benefit and drawback was explained to the patient; specially regarding the immediate load possibility due to bruxism.

The patient chose option D because of the obvious advantages regarding aesthetics, but being aware of the special care it would imply.

## Treatment

- Step one was clinical and radiographic evaluation of the patient. Photographic records are taken, Rx and CBVT, as well as alginate impressions for the study model on the semi-adjustable articulator (Artex).
- We carefully drilled from mesial to distal to separate the vestibular root from palatal root. We perform the periodontal ligament removal using a 15c scalpel.
- The palatal root is carefully extracted so the vestibular one is not pushed or rotated at any moment. In (Figure x), we can see how deep the fracture was on the palatal root.
- We extracted the rest of the palatal root.
- The crown was then drilled horizontally to gum level.
- Using a diamond drill, we started to shape the remaining root in a U shape. It would be enough to leave only a vestibular shield, but in this case the shield left is from mesial-vestibular angle to distal-vestibular angle.
- Once the U shape was achieved, using a pear-shape diamond drill, we drilled the shield to 1mm under bone level. Different techniques are described regarding to the shield level and width. The thickness should be 1.5mm-2mm. And the minimal length should be 5mm. The most important issue regarding the measures of the shield is not to leave any soft tissue remaining (nerve, canal vascular tissue, cyst).
- Using a ball diamond drill, the edge of the shield must be smoothed, leaving no sharp edges.
- Once the shield is completely drilled and the palatine socket cleaned, we drill the implant bed at the 3D location chosen. Due to the bone anatomy, the ideal position would be for the implant axis coming up the palatal area. It is vital not to touch the shield while drilling, as it would compromise the vascular net.
- After placing the Zinic MT implant, thanks to the Zplus multifunctional mount, we checked its correct 3D position. The implant is placed at 1mm subcrestal bone level to compensate the bone reabsorption when placing a post-extraction implant. The implant would be placed as near as possible the shield, but never in contact with it. Any movement of the shield would compromise its integrity and the final result.
- We check the Zinic MT implant's primary stability, using Osstell, and it registered an ISQ value of 74, a correct value to perform immediate loading.
- We use the Zplus as a temporary or provisional abutment to allow for a provisional crown. Special care must be taken when creating the emergence profile for the crown. It must give enough space for the soft tissue to heal over the shield, at least

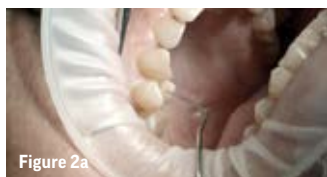

Figure 2a

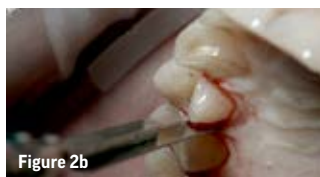

Figure 2b



Figure 3

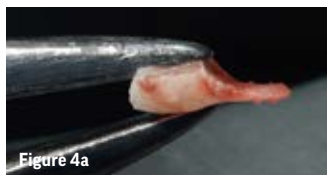

Figure 4a

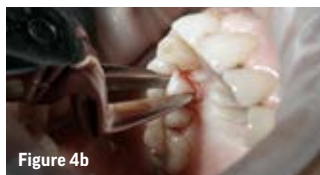

Figure 4b



Figure 5

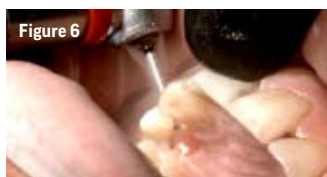

Figure 6

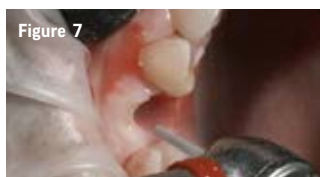

Figure 7



Figure 8

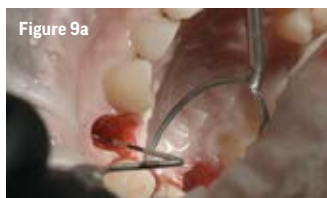

Figure 9a

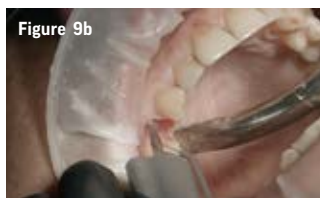

Figure 9b

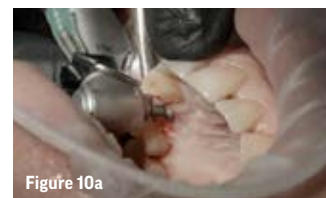

Figure 10a

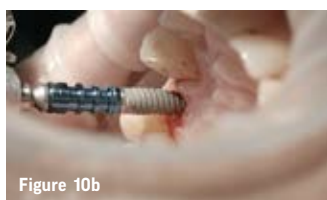


Figure 10b

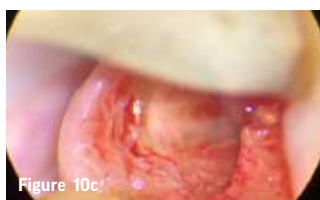


Figure 10c

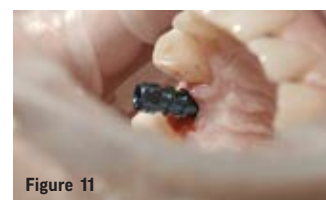

Figure 11



Figure 12

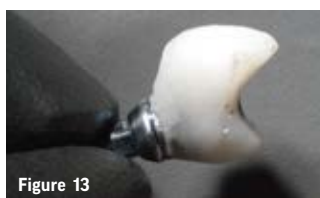

Figure 13

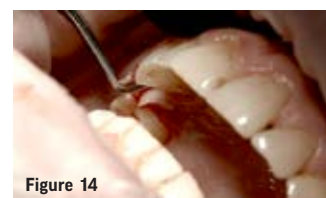

Figure 14

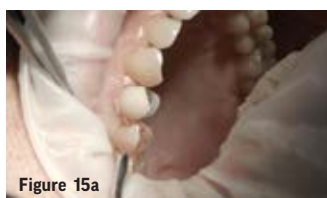

Figure 15a

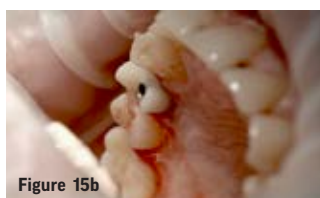

Figure 15b

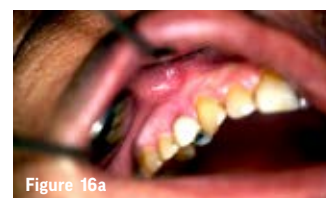

Figure 16a

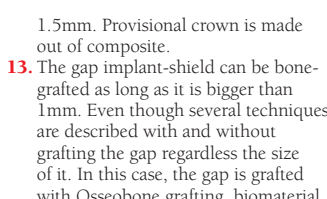


Figure 16b

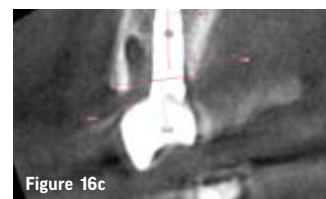


Figure 16c

1.5mm. Provisional crown is made out of composite.

- The gap implant-shield can be bone-grafted as long as it is bigger than 1mm. Even though several techniques are described with and without grafting the gap regardless the size of it. In this case, the gap is grafted with Osseobone grafting, biomaterial mixed with PRF and completely covered with a PRF membrane.
- The provisional crown is screwed on top and no stitches are required.
- Final X-rays and CBVT were performed.

## Summary

Nowadays, a successful treatment involves a long term survival not only of the implant, but the surrounding tissues


involved in aesthetics.

Although a PET is a sensible technique and requires certain skills to be performed successfully, the results are highly satisfactory, especially using high performance materials like the Zinic MT implant.

Literature describes as satisfactorily the medium and long term results of this technique. Even though more studies are

being made worldwide as the PET has shown to be effective. It not only stops the bone loss, but stops the collapse of the gingiva, papilla and therefore the aesthetics. Further surgery to correct these issues is not required. **D**

For a list of references contact [julian@dentistry.co.uk](mailto:julian@dentistry.co.uk).



# Dentistry

Date: 1 November 2018

Page: 24-29

Country: UK

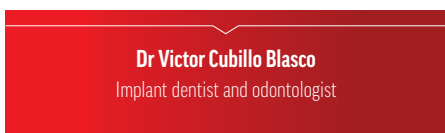
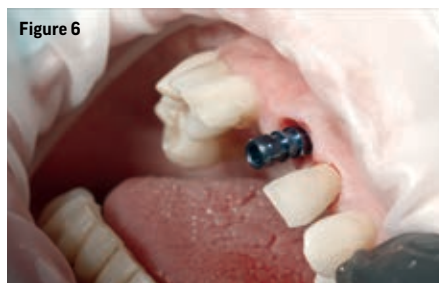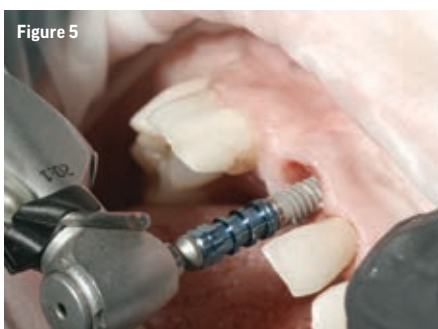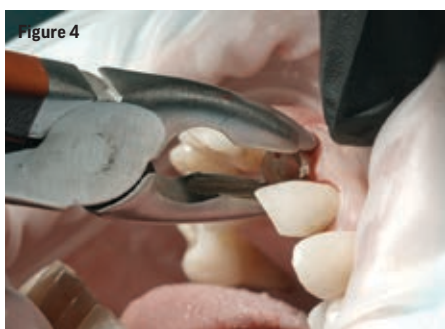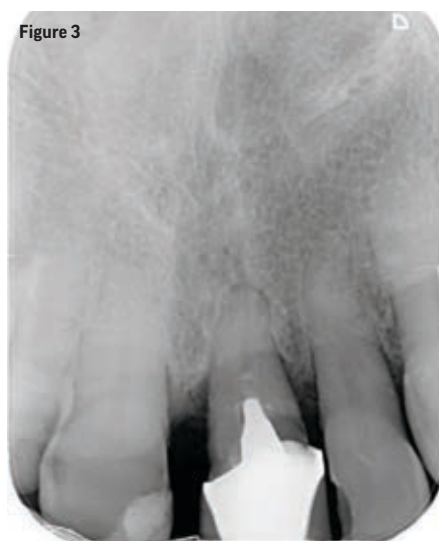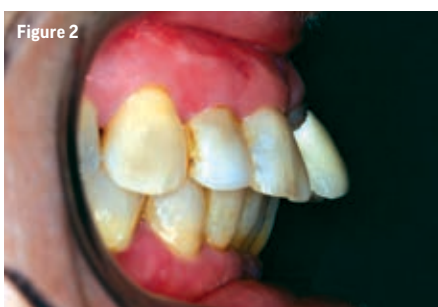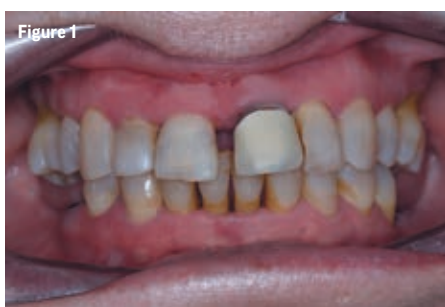Article name: IMMEDIATE IMPLANT LOADING:  
AESTHETICS AND FUNCTIONALITY

Products: Zinic®MT

Dentist: Dr. Víctor Cubillo Blasco

# Immediate implant loading: aesthetics and functionality

**Victor Cubillo Blasco** finds the best possible solution following the extraction of a tooth in the aesthetic zone



**Dr Victor Cubillo Blasco**  
Implant dentist and odontologist

The lack of a single tooth in the aesthetic zone can cause major loss of self-confidence and self-esteem to anyone. It can provoke patients to stop smiling, and has the inevitable consequence that their character often drastically changes.

For a dentist, there are other factors that play a significant role: functionality and bone volume reduction may affect the patient's wellness to an extreme he or she might not even realise. However, the solution is a common procedure that an expert performs quite often. For successful results, conveying confidence and expertise to the patient, and counting on great laboratory work, clinical skills and materials are indispensable.

## Patient diagnosis

The patient presented with periodontitis around the UL1. The patient claimed that root canal treatment had been performed on the tooth five years earlier, however the X-ray did not confirm this.

The bone loss around the UL1 and the mobility of it made extraction the only solution available. The mobility and the position of the UL1 had a great impact on aesthetics and functionality (Figures 1 and 2).

## Treatment options

Considering the only solution for the UL1 is extraction, there are three possible treatment options:

**1. Removable prosthesis placement.** The only advantage related to this option is its economy. Aesthetics and comfortability did not fit the patient's demands.

It did not prevent alveolar bone reabsorption and it would require future surgical interventions to preserve both the bone and soft tissues.

**2. Drilling UR1 and UL2 for ceramic bridge placement.** The placement of a ceramic bridge fulfilled the patient's requirements. However, it did not prevent bone reabsorption nor gingival recession in the long term. In order to correct these issues, future interventions and new ceramic prostheses would be required.

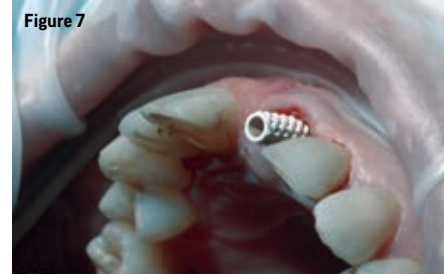**3. Implant placement to replace UL1.** Intraosseous implant insertion is the most aesthetic and functional option in the short- and long-term. For favourable cases, as the one described, the best option would be post-extraction implant placement and provisional immediate load. This procedure would require the bone grafting of the alveolar gap. In this way, aesthetics, bone volume and gingival anatomy would be preserved. Preserving interdental papilla at the front area is the key to achieve natural aesthetics.

After discussing all the options, the patient choses the third. Furthermore, considering the UR1 is restored with a composite veneer, I proposed restoring the tooth with a zirconia-ceramic crown.

## Treatment

The patient undergoes clinical and radiographic evaluation. Radiographic (Figure 3), CBCT and photographic records – as well as an alginate impression – are taken. The patient is informed on the diagnosis and the different treatment options. After assessing the information, the patient decided on implant treatment to replace the UL1. The implant would be immediately provisionalised and loaded, with zirconia crowns placed on the UR1 and UL1.

Dr Felicitia Lorenzo and I placed a Zicom Zinic MT implant. Thanks to the cone-shaped and compressive design of its body, this implant offers an ideal primary

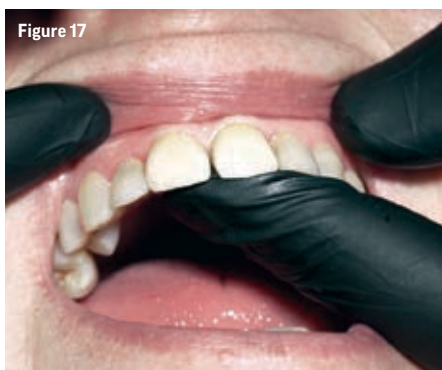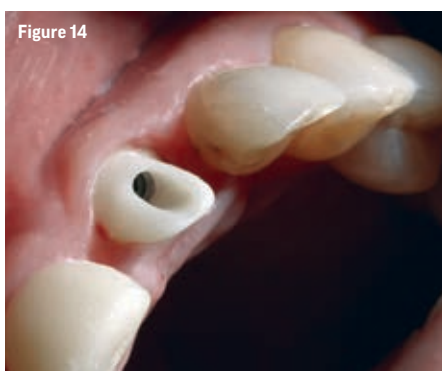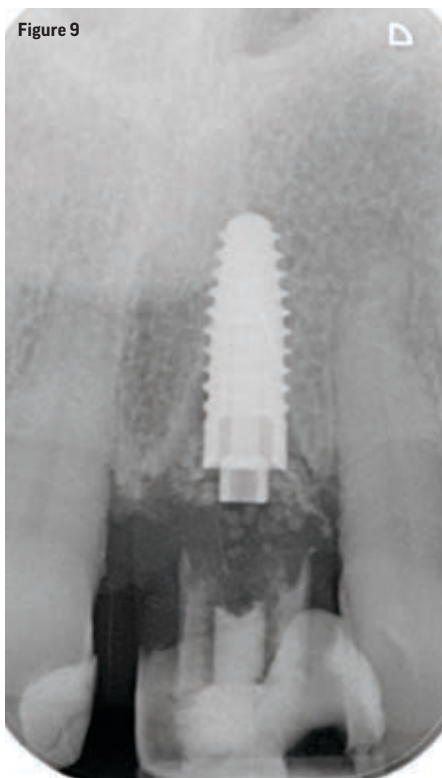
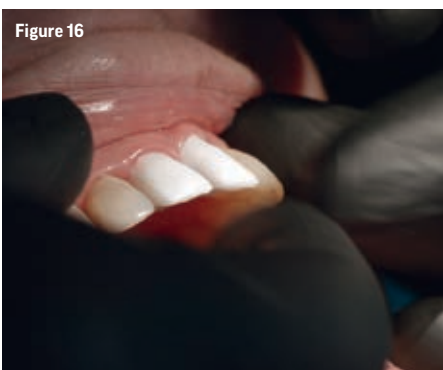
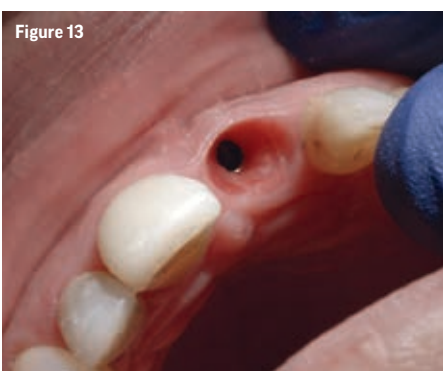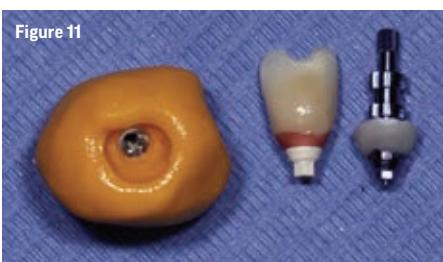


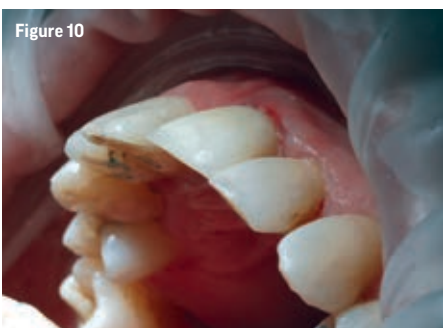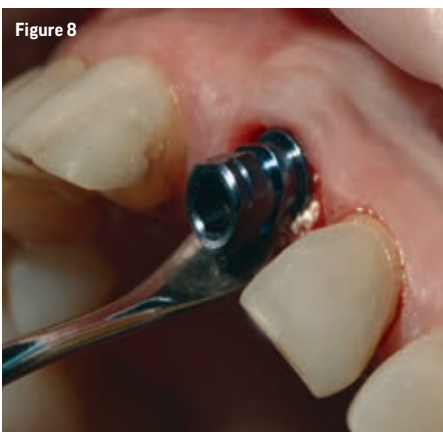stability for these cases. The hexagonal internal connection and its mechanised ring offers the perfect stability for soft tissues in the long-term.

We perform the periodontal ligament detachment, and carry out the atraumatic extraction (Figure 4).

After careful cleaning of the socket, the implant socket is drilled. The ideal position for the implant would be for it to be placed palatally. However, in this specific case, for the axis of the implant to stay inside the correct area, it needed to be placed incisally (Hämmerle, Chen, Wilson, 2004; Lee et al, 2014; Tabrizi and Azizi, 2013). The result of this placement meant that a cemented ceramic restoration would be needed.

Due to bone reabsorption, the implant is placed 1mm infra-bone (Figure 5) (Huynh-Ba et al, 2010; Botticelli, Berglundh, Lindhe, 2004; Al Amri, 2016).



The primary stability of the implant is checked using Osstell, and confirms a correct value to perform immediate loading of the implant.

After placing the Zinic MT implant, its position is checked and is correct, thanks to the use of the Zplus abutment (Figure 6). The abutment is replaced for a provisional polyetheretherketone (PEEK) abutment (Figure 7). This abutment is chosen due to its great biocompatibility with soft tissues and its practicality when manufacturing provisional composite crowns.

We use a PMMA tooth to elaborate the provisional crown while pasting it to the provisional PEEK abutment with Visiolink adhesive and fluid composite, Crea-Lign A2 colour. Extraorally, we shape the gingival emergence with fluid composite (Crea-Lign pink colour), before being polished (Degidi et al, 2013).

The Zplus abutment is relocated to prevent the insertion of osseointegrated bone grafting biomaterial (made of beta tri-phosphate calcium) inside the implant (Figure 8). Bone regeneration of the socket-implant gap prevents bone reabsorption of the socket, preserving the gingival stability (Tomasi et al, 2010; Calvo-Guirado et al, 2015; Quaranta et al, 2016; Shakibaie-M, 2013; Cardaropoli, 2014).

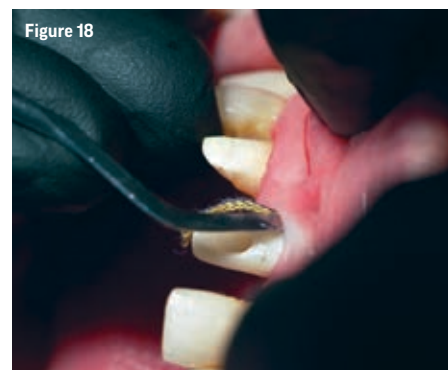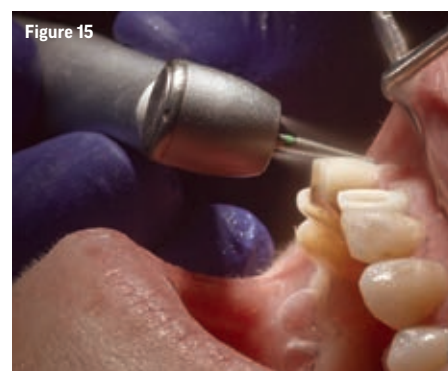The provisional crown is placed, screwed and splinted to the UL2 to manage greater stability (Figures 9 and 10).

Four months pass before the provisional crown is removed. This allows for bone integration and soft tissue stabilisation (Caneva et al, 2010). Once the crown is removed, the stability of the implant and soft tissues surrounding the implant are checked (Cardaropoli et al, 2015; Yan et al, 2016).

Using the provisional crown as a model, the gingival emergence is copied in an impression transfer ready for the laboratory to mimic (Figure 11).

A milled zirconia abutment over a manufactured titanium post is created at Ziacor CAD/CAM milling centre (Figure 12). This abutment is checked intraorally, paying special attention at the critical and subcritical level areas, so the gingival peak and margin are shaped correctly. Once the post is placed with 30Ncm torque, it is not removed, following the 'one abutment one time' technique (Figures 13 and 14).

The URI is prepared for the zirconia-ceramic crown, and an impression of both preparations is taken. Provisional crowns are placed while the definitive ones are manufactured (Figure 15). Ziacor CAD/CAM milling centre manufactures two zirconia caps for both crowns in the URI and the UL1 (Figure 16). Once the





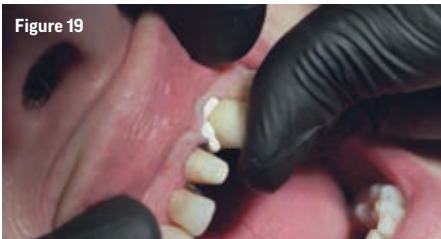

Figure 19

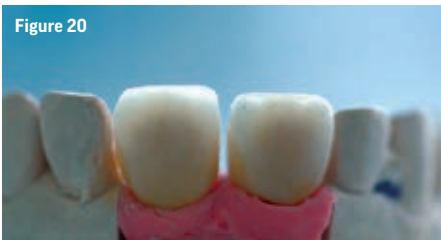

Figure 20

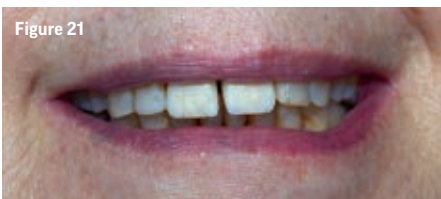

Figure 21

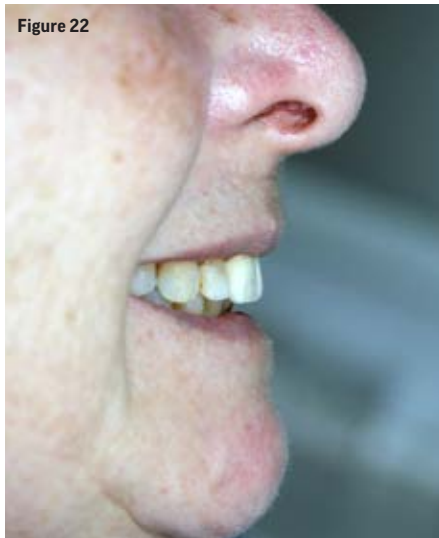

Figure 22

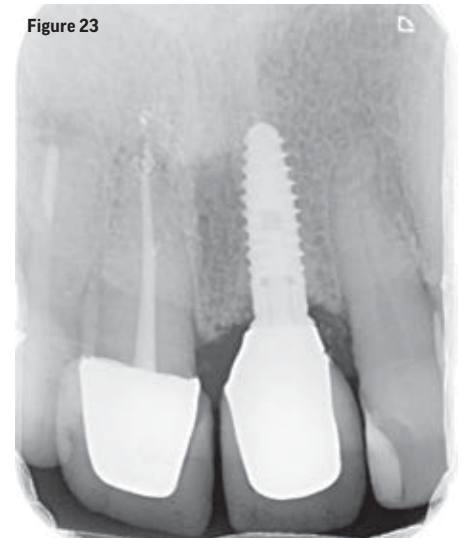

Figure 23

caps are verified, they are loaded with ceramic to be verified again intraorally (Figure 17).

Finally, both crowns are cemented. UR1 is cemented with Panavia resin cement and the implant at UL1 is cemented with Implant Cem. Retraction cord is used to prevent any remains of the cement around the implant (Figures 18 and 19).

The final result is a crown over the implant with a perfect implant-post adjustment, and the gap to the cemented crown at 3mm of the implant, reducing peri-implantitis risk and supporting the biological sealing (Figures 20-23).

**Summary**

Immediate loading after extraction has been largely described in literature and different techniques have been developed. Some authors graft the gap implant-socket with bone substitutes while others don't graft it at all. Some techniques describe the use of allogeneic membranes and some techniques describe the use of PRF (Salgado et al, 2014; Fenus et al, 2010; Kim et al, 2016; Gupta et al, 2012; García Gargallo et al, 2016; de Medeiros et al, 2016).

A flap may be raised, depending on the need to graft the vestibular plate or not.

The goal of every technique is to replace the dental piece immediately after extraction, while also minimising the bone loss and maintaining the soft tissue architecture surrounding the implant.

This soft tissue, specially the papilla, is the key factor for an aesthetic and satisfactory result.

The correct management of the contact points, the available distance for the soft tissue to biologically seal around the implant and the clinician's ability to modify the critical and subcritical area of the emergence profile are the prosthetic skills the clinician must handle carefully in order to achieve a satisfactory and aesthetic result.

From the surgical part of the process, a correct diagnose and treatment plan are essential. For long-term implant survival, the choice of implant to be used and its correct 3D position, as well the right prosthetic abutments and materials, are vital.

A skilled clinician using the right materials and techniques is all the patient needed to face her fears about implants and surgery. With only one surgical act, the patient's appearance and self-esteem improved greatly. From that point forward, the patient was very pleased and relaxed during the prosthetic procedure as the surgical procedure had given her more than she expected. **D**

References are available from julian@dentistry.co.uk.

Offer valid until 12/21/2018



Visit us at:  
**Implant Dentistry Show**  
 26th January 2019  
**Stand 47**  
 Novotel London West

**60 implants + 2 Surgical Boxes  
 + Trip to Madrid (to visit our facilities)**

Voucher Code: 60MADRID2018\*

**Only**  
**£6,000**  
 VAT excluded  
 Offer is valid until December 2018




**Zinic<sup>MT</sup>**





\* Voucher Code: 60MADRID2018  
 Offer is valid until the end of December 2018.  
 Call to +44 129 332 4013 for more info, book your appointment with local sales reps and use your voucher.  
 Offer is not available in conjunction with any other promotions.



**MaXILLARIS**

Date: December 2017

Page: 68

Country: Spain

Article name: CONICAL BODY WITH REDUCED  
ANGLE DOUBLE THREAD AND ATRAUMATIC APEX.

Products: Zinic<sup>®</sup>MT

Dentist: Dr. Víctor Cubillo Blasco



## ZINIC<sup>®</sup>MT

**Manufacturer**

Ziacom Medical S.L.

**Distributor in Spain**

Ziacom Medical (own network).

**Market introduction year**

2004 (Spain).

**Shape**

Conical body with reduced angle double thread and atraumatic apex.

**Prosthetic connection type**

Compatible internal hexagon.

**Core material type**

Zitium<sup>®</sup>: high-pressure grade 4 titanium.

**Surface material type**

Osseonova<sup>®</sup>: sandblasting and double etching.

**Available lengths**

8,5 -10 - 11, 5 - 13 mm.

**Available diameters**

3,6 - 4 - 4,4 - 4,8 mm.

**Osseointegration period**

From 6 to 8 weeks.

**Cases in which immediate loading is accepted**

High primary stability (ISQ > 70).

**Long-term scientific studies**

Available.

**Prosthetic abutments type**

Prosthetic solutions: provisional abutments (PEEK or titanium), definitive abutments for cemented and screwed restorations, transepithelial abutments, overdentures abutments and CAD/CAM Ti-bases.

**Guarantee type**

Lifetime guarantee on dental implants.

**Additional information**

ZPlus<sup>®</sup> multifunction abutment: implant mount, impression transfer or provisional abutment for cemented-screwed restorations. Scanbodies are available for CAD-CAM prosthetic design. ZIACOR<sup>®</sup> CAD-CAM Service.

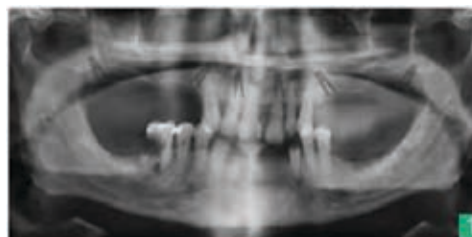Kiran<sup>®</sup> clinical screw: high performance with surface treatment that reduces the risk of screw loosening.

Tx30<sup>®</sup> variable rotation abutment: for the correction of implants with unfavourable angulation.

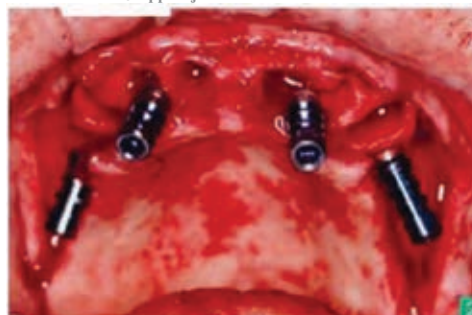Zinic<sup>®</sup>3D: Surgical planning software for guided surgery.

Immediate complete upper and lower rehabilitation with delayed implants in the posterior region of the upper jaw. Courtesy photos by Dr. Victor Cubillo Blasco (Tenerife, Spain).

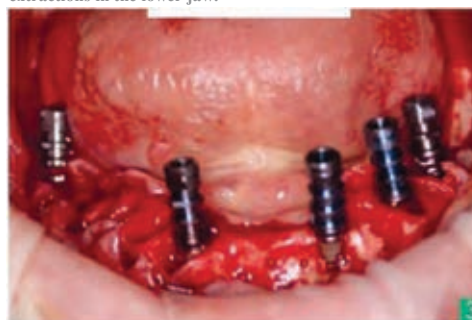Pre-operative X-ray



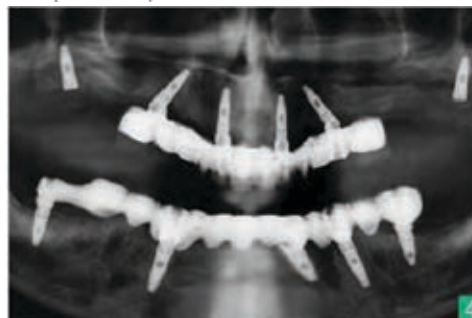
Immediate implants placement with multiple dental extractions in the upper jaw.



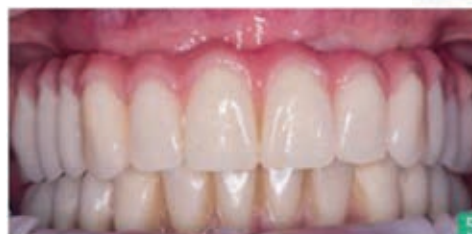Immediate implants placement with multiple dental extractions in the lower jaw.



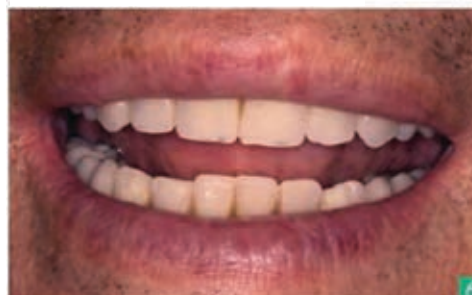Post-operative X-ray



Hybrid prosthesis placement



Final result





Date: December 2017

Page: 82

Country: Spain

Article name: A COMPLEX PERIODONTAL CLINICAL CASE  
SOLVED SUCCESSFULLY THROUGH IMMEDIATE LOADING

Products: Osseos®BCP and T-Gen®

Dentist: Dr. Víctor Cubillo Blasco

# A complex periodontal clinical case solved successfully through immediate loading

## Preamble

*The studies and praxis of immediate loading have managed to situate this technique as a predictable practice in contemporary implantology, reaching a success rate of over 90% in the appropriate cases for its application. Although there is still a significant prejudice to its exercise among a considerable spectrum of dental community, the successful resolution of complex cases with its use demonstrates not only its constant evolution, but also adds favourable positions to the technique. The main requirement is, in many cases, the ability to identify suitable cases for their application, whose number is increasing thanks to innovation in implants, regeneration materials and surgical and prosthetic techniques.*

◆ Contact  
info@arte-dental-lauch.com

The clinical case presented below will illustrate how these factors, the patient's experience and commitment, as well as the correct application of immediate loading and optimal bone regeneration will be essential to successfully save an advanced periodontal state in a patient who has just undergone a serious oncological process.

Implantology is constantly developing to satisfy the needs of a society where immediacy prevails. Even though it is not currently the most chosen practice, numerous studies have demonstrated the feasibility of immediate loading, which together with continuous improvements in surgical techniques and materials allow a constant improvement in the results offered to patients.

Advances in dental implantology are directly linked to the studies of P.I. Brånemark and collaborators. The first experimental work of this research group(1) led to the development of a completely new concept to replace missing teeth using endo-osseous implants. A few years after the publication of P.I. Brånemark, its protocol began to be questioned. In 1976, the Swiss Philippe D. Ledermann placed the same day of the intervention on one-piece overdentures with a bar on intraforaminal implants(2). Schroeder(3), following the same method, demonstrated histologically an intimate bond between the

bone and the implant. Babbush et al.(4), Buser et al.(5), Schnitman et al(6) achieved, in the medium and long term, a success rate of 88 to 97% for implants with immediate loading in the anterior mandibular area.

After several years of extensive research, basic criteria for immediate loading were established in 2002(7) and are detailed below:

1.- Location: The ideal location of the implant is mainly determined by the bone quality, being the interforaminal region the one with the highest success rate.

2.- State of healing of the receptor bone bed: Most works carry out the immediate loading in areas of mature bone(8-18); however, others propose it on implants placed at the very moment of the extraction or in fresh socket after extraction(19-24). The common criterion is always the presence of healthy and mature bone.

3.- Implant type and surface: At first, the type of implant and its surface seemed crucial. Today it is not so decisive. Tarnow et al.(16), in a sample of 107 implants, used 4 different threaded implant systems and concluded that immediate loading is feasible in all cases.

Chiapasco et al.(12) used 776 threaded implants

from different systems in mandibular overdentures on 4 anchors, with a success rate of 96.9%.

4.- Implants length: Implants are at least 10 in length and 3.3 in diameter. Gatti et al.(25) excluded patients with mandibular bone availability unable to accommodate implants of at least 10 mm in length and 3.3 mm in diameter. The immediate mandibular implants of Ericsson et al.(9) followed the same length criteria, as did the 107 implants of Tarnow et al.(16), placed in the maxilla and mandible; and the 776 implants of the study of Chiapasco et al.(12).

5.- Type of prosthesis: For Maeglin, Gatti et al., Chiapasco et al.(15) among others, the splinting of the implants with rigid frameworks puts a success of between 96 and 97.5%.

6.- Initial stability: Malo et al.(20) excluded in their immediate loading protocol the implants inserted with a torque less than 32 N/cm, a value that today has been replaced by the ISQ, with a minimum value of 60 to perform an immediate full arch loading.

As was the case with Brånemark, these criteria are also being discussed thanks to continuous innovation in implants, regenerative materials and surgical techniques, which expand the range of cases in which immediate loading treatment is successful. Immediate implant loading is currently a predictable procedure; its success in the mandible is

between 90 and 100%. In the maxilla this is lower, varying between 66 and 95.5%. In the immediate loading on implants, the success rate varies between 82.4 and 97.2%. Next, a case will be presented that will illustrate how the evolution of implantology has reached a state capable of satisfactorily overcoming complex cases.

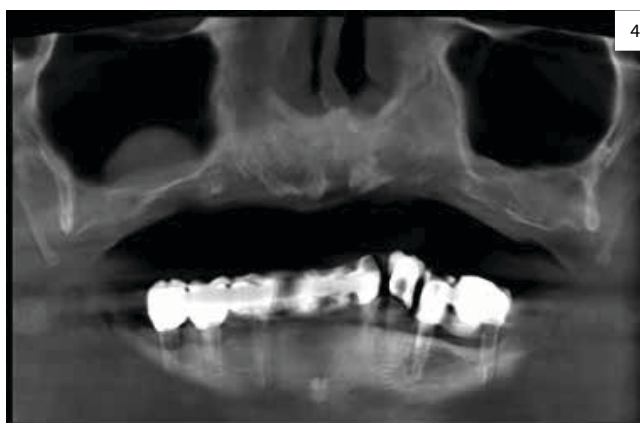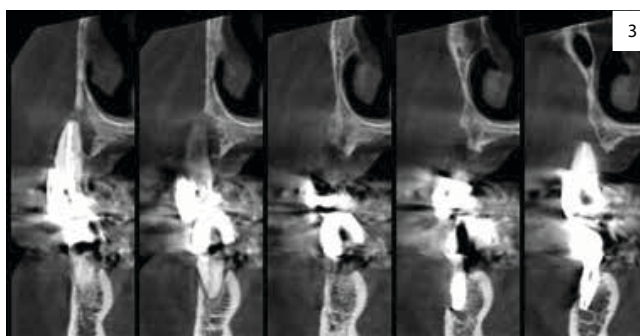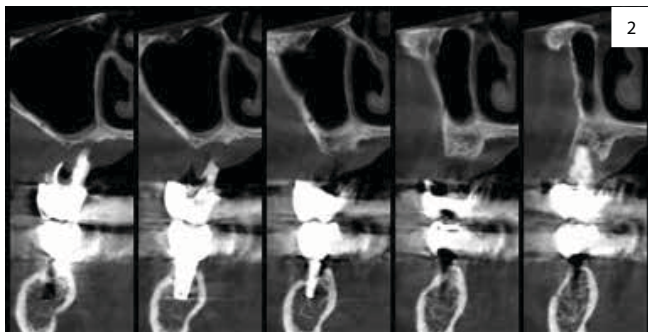
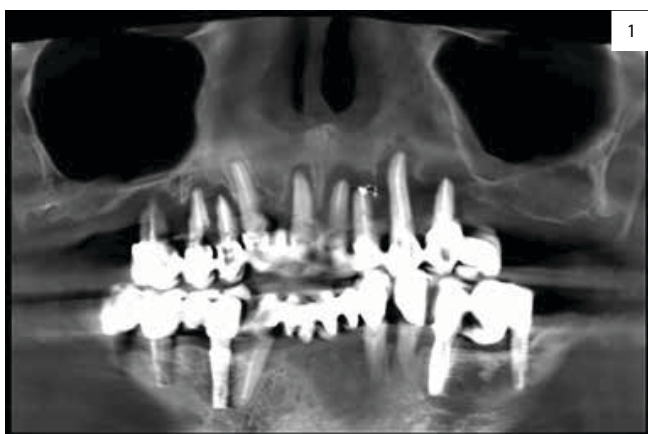#### Clinical case

66-year-old patient, ex-smoker, with advanced periodontal disease, refers to being under treatment for depression and having been successfully operated on for breast cancer. Nine months have elapsed since the end of her oncological treatment.

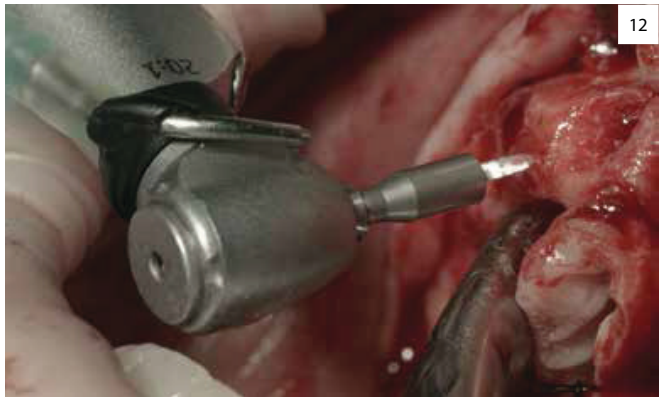
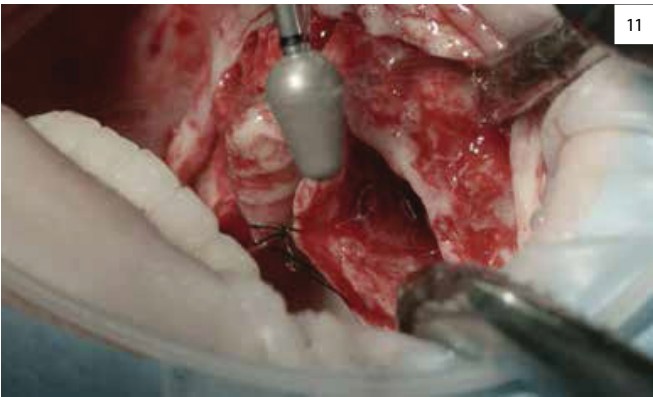
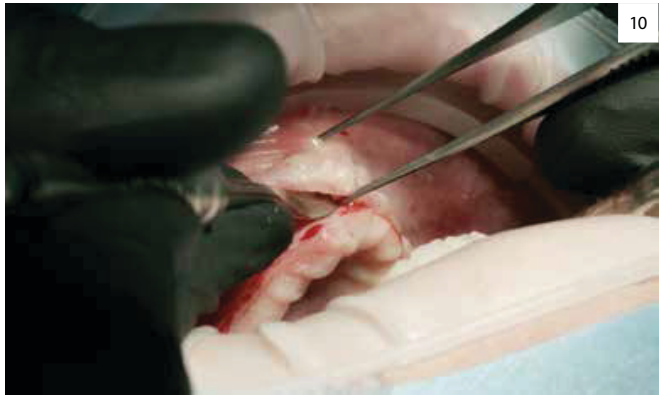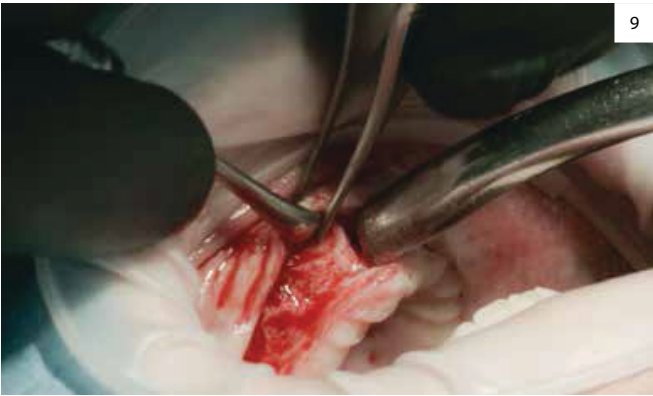
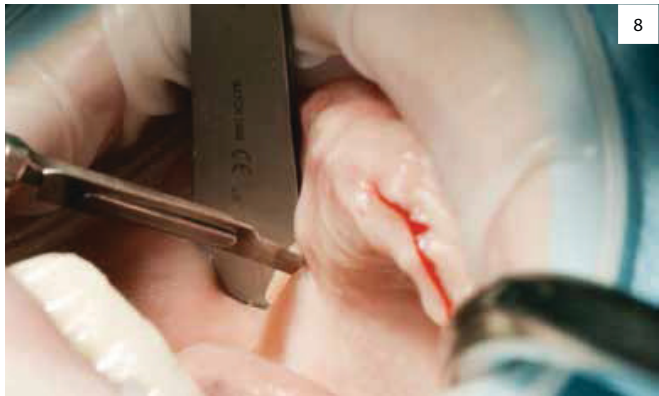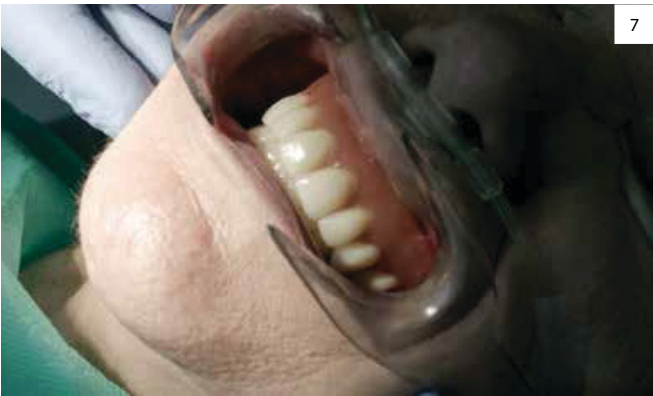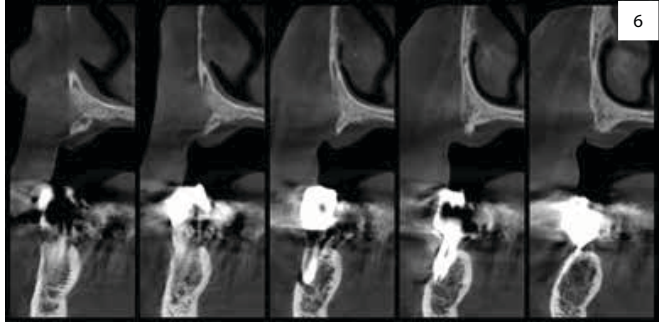
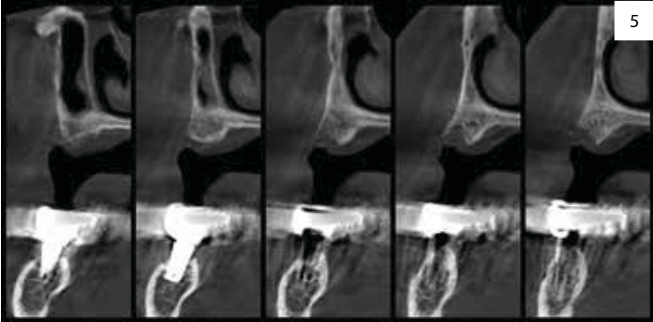
The patient is psychologically motivated by having overcome a complicated illness, but the precariousness of her dental aesthetics accentuates her depressive state. She is insecure and reveals low self-esteem. The lack of confidence in her physique and in her expression constantly threatens her self-esteem. After having undergone a long medical process, the immediate loading had the ideal characteristics to improve their physical appearance and regain self-confidence in the short/medium term. She comes to the dental office because of the impossibility of eating due to the mobility of all the

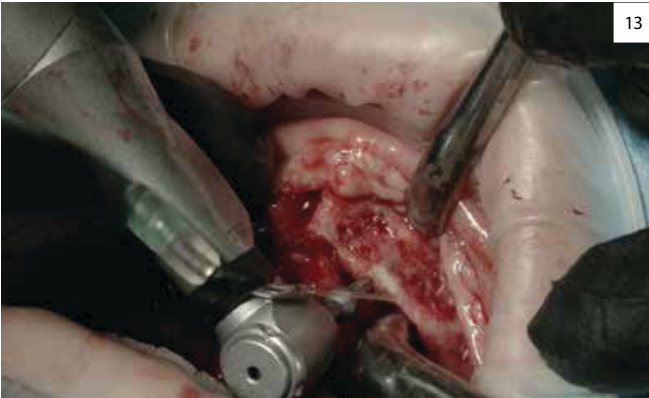


Dr. Víctor Cubillo.  
Licenciado en Odontología y Cirugía Oral. Director médico clínica Artedental (Tenerife).  
Coinventor solución protésica de carga inmediata ArtOn4®.  
Profesor de seminarios y estancias clínicas.

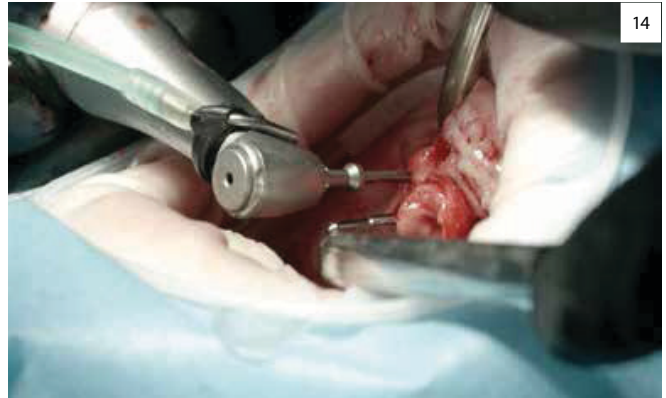


> **SURGERY**





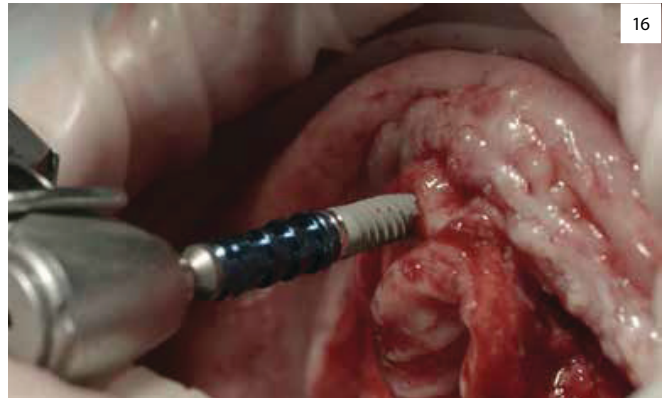
13



14



15



16

pieces of the upper arch, an issue that revealed in public their aesthetic deficiency, generating situations of social stress.

The radiological study carried out by CBTC showed large areas of bone resorption and the presence of several periapical lesions. The right maxillary sinus was clean, and the left had only a slight inflammation of Schneider's membrane (photos 1-3). Given the high risk of failure in the case of post-extraction implants, it is decided, in a first surgery, to extract all the upper pieces and eliminate all the periapical processes, in addition to the granulation tissue. An antibiotic is prescribed as an adjuvant treatment (Amoxicillin/Clavulanic Acid 875mg/125mg for 7 days, starting 5 days before the surgery).

The bone tissue is not regenerated, limiting the action to the application of 12 A-Prf membranes (photo 23) to accelerate healing, cure and regeneration of the tissues (photo 27). A complete prosthesis is placed with Tokuyama® soft relines (photo 7), and after waiting 12 weeks, an upper maxilla is obtained in a state of health suitable for implant placement (photo 4). There are still areas of narrow crest and defects that are now susceptible to regeneration using GBR (Guided Bone Regeneration) techniques

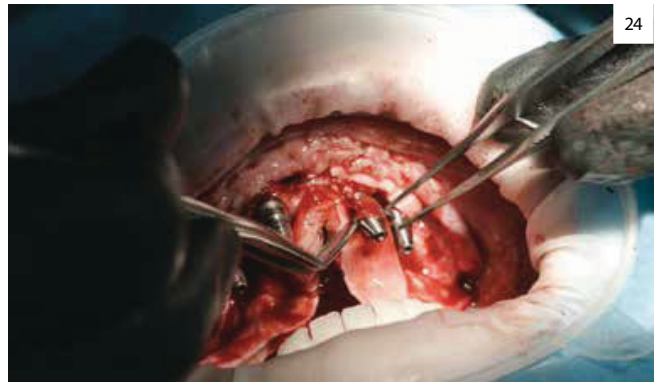
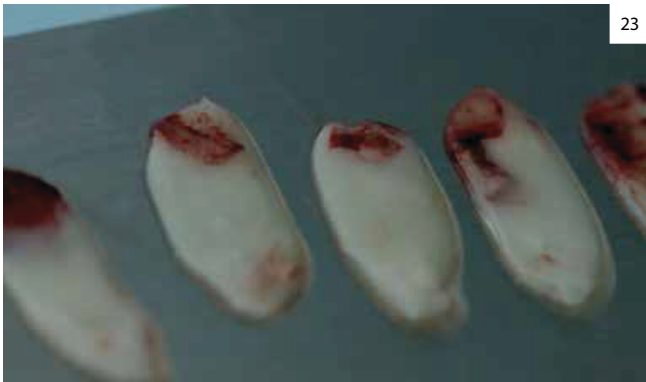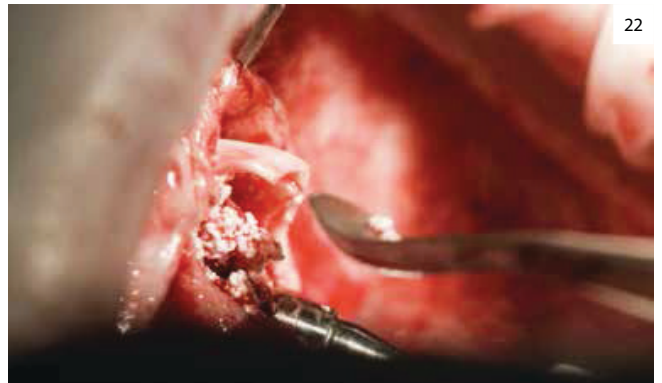
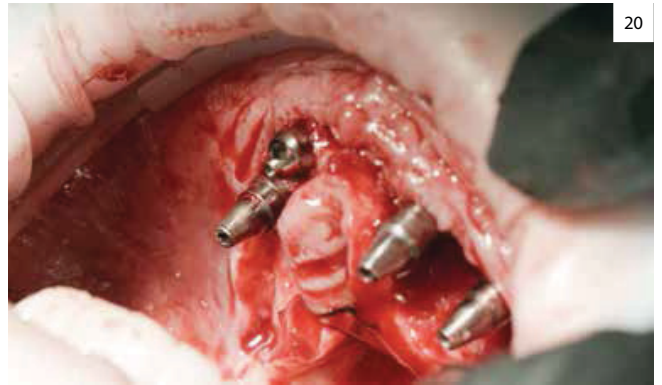
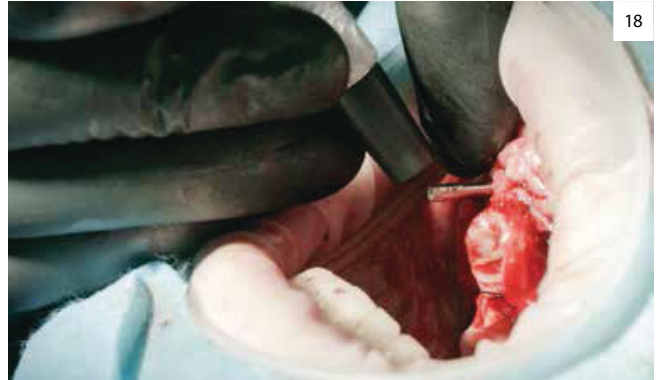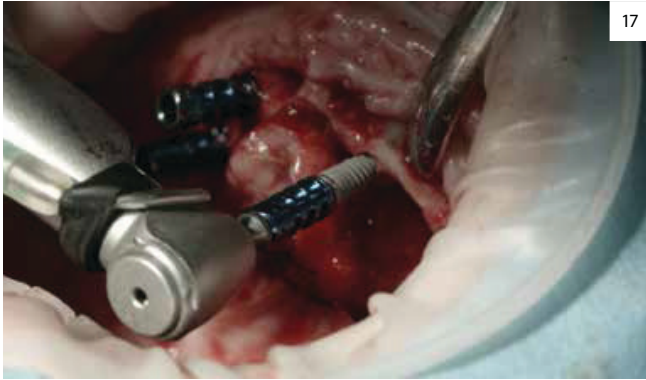
(Photos 5-6).

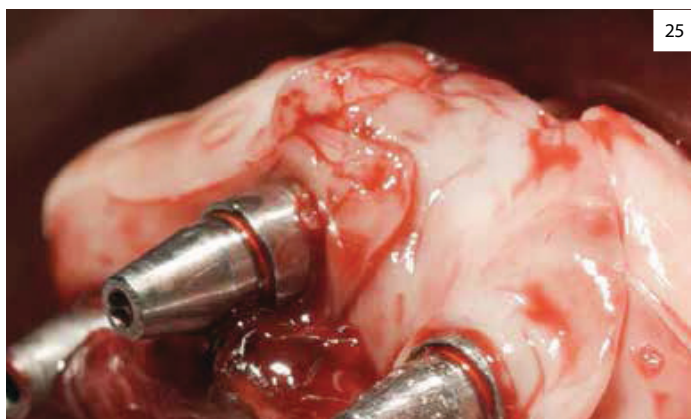The alternative treatment would have been to regenerate the bone crest in a second surgical act, and then in a third stage of surgery proceed to place the implants. However, this option would have delayed the placement of the fixed prosthesis by 6-9 months. Thanks to practical experience and the correct handling of surgical techniques, regeneration materials and especially the occlusal design and masticatory functionality, immediate loading is carried out.

A crestal incision is made at full thickness from the right to left maxillary tuberosity, with slight vertical discharges at the level of both posterior structures (photo 8). This incision will allow a correct closure without tension in the area to regenerate. The periosteum is removed to the base of the vestibule (photo 9-10), leaving an irregular but healthy-looking maxilla visible, with the palatal cortical practically intact (photo 9). With the surgical handpiece, abundant irrigation and a diamond bur, the bone crest is regularised (photo 11); and with a 2-ball diamond bur, drilling is carried out in the cortical for a correct vascularisation of the bone grafts.

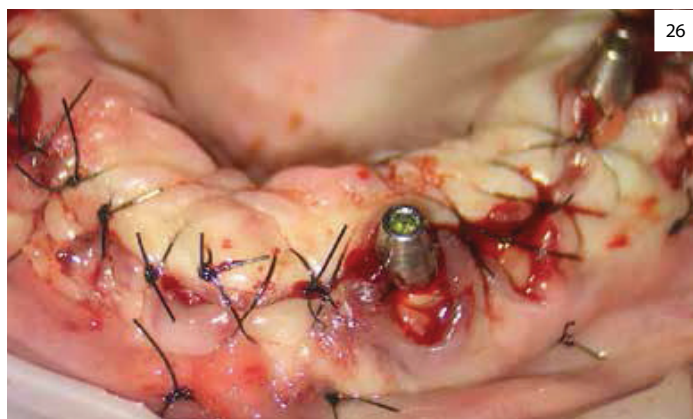Once the maxilla has been prepared, the position of the implants is marked (photo 12). The implants are



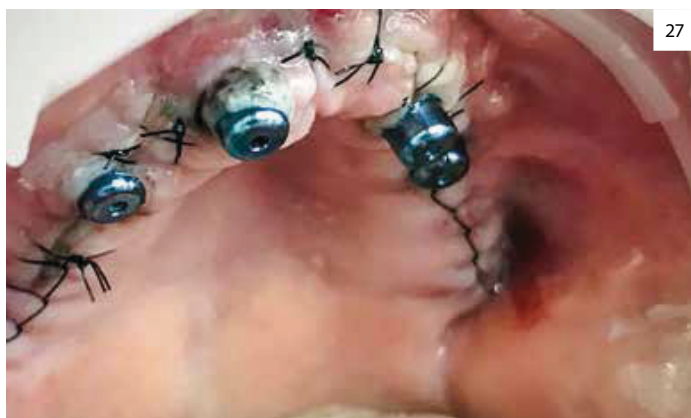



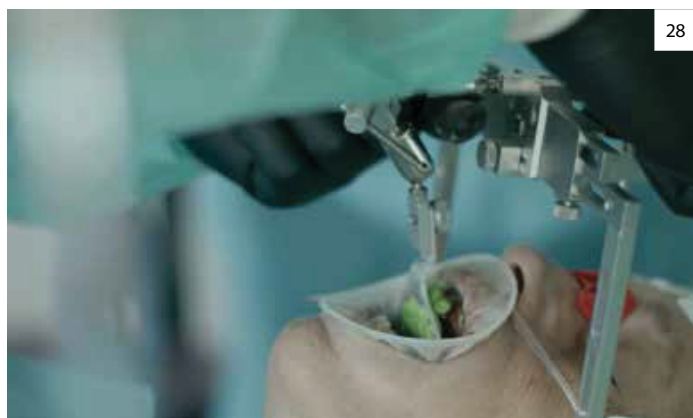25



26



27



28

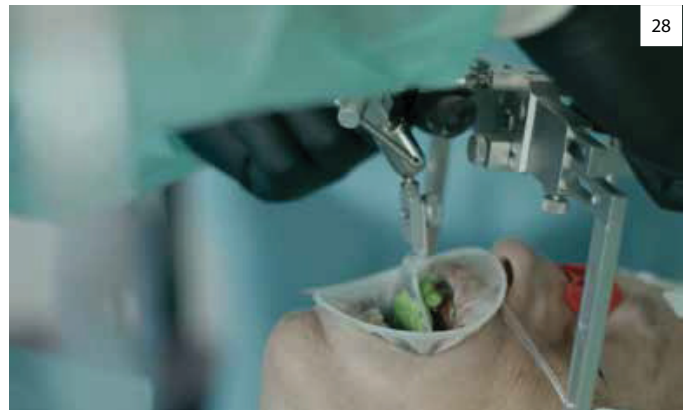
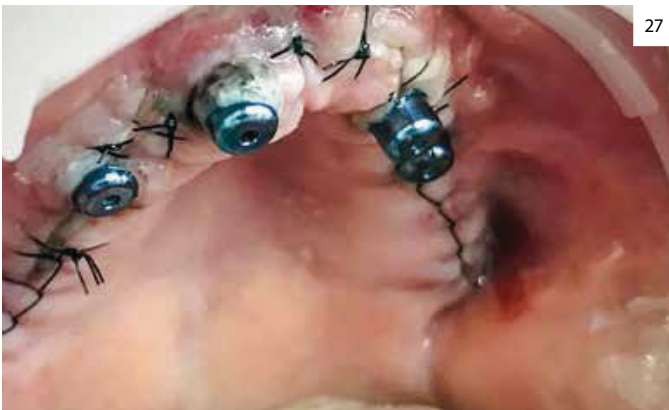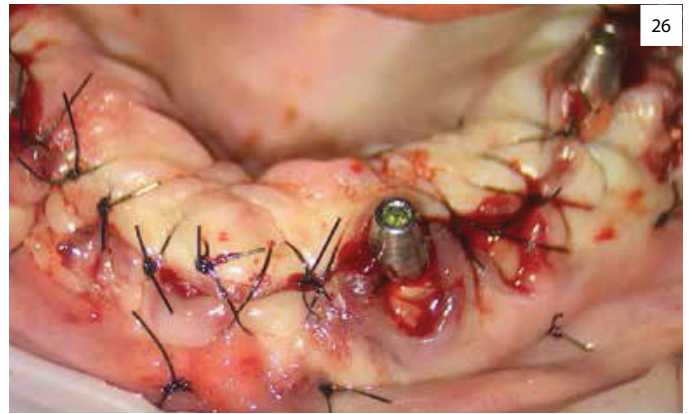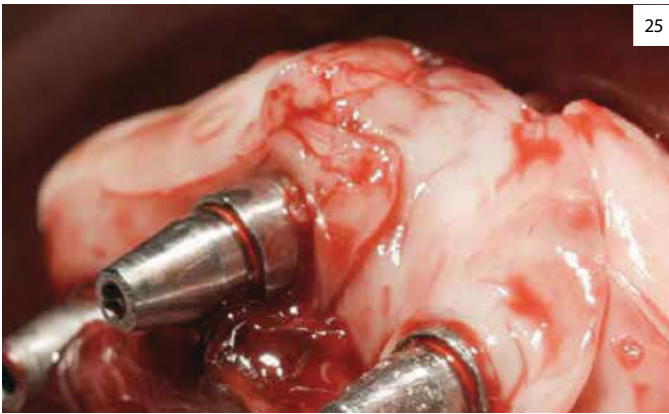placed in intimate contact with the palatal cortical to gain stability, seeking to use all the available bone height (photos 13-17). A symmetrical distribution of the implants and parallelism is calculated to allow a homogeneous distribution of the occlusal loads in the bone(26) (photo 17).

Once the receptor sites have been prepared, 4 Ziacom® ZinicMT® implants of 3.60 mm in diameter and 10 mm in length are introduced in anterior sectors, and 11.5 mm in length in posterior sectors (photos 16-17).

In this case, only the 4 implants in the anterior area are immediately loaded due to their adequate primary stability. The implants in the maxillary tuberosities will be submerged during an integration period of six months, and then proceed to their deferred loading, since they did not have the stability values necessary for immediate loading. In cases such as this, a combined load is chosen, offering the advantages of immediate loading in anterior area and reinforcing it with the deferred loading of posterior implants. The ISQ values and the patient's collaboration will be the determining factors to carry out the immediate loading. The implants are placed

with 35Ncm of insertion torque, always verifying the primary stability of the implants using Osstell® and obtaining ISQ values between 65 and 72 (photo 18). If an implant does not reach the recommended value for immediate loading, it will be loaded if the value is close to the recommended value. These implants with less stability integrate perfectly if a correct occlusion and occlusal load is established, which is achieved by adding experience to the splinting offered by the immediate prosthesis chosen, whose base is a titanium framework. Because occlusal loads are distributed over all implants, an implant that does not fulfil with the established ISQ entails a risk that could be assumed, since micromovement will be equal to or less than that of the rest of the implants (27-29).

To improve the stability of the peri-implant tissues, fundamental in immediate load treatments with multiple implants, transepithelial abutments are placed to correct the angulation of the definitive abutments (photos 19-20), facilitating not only the insertion of the prosthesis, but also its aesthetics. Following the "one abutment one time"(30) theory, these abutments will not be removed again, respec-



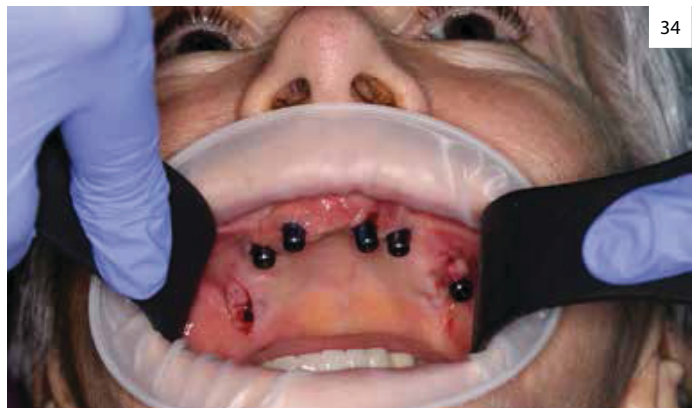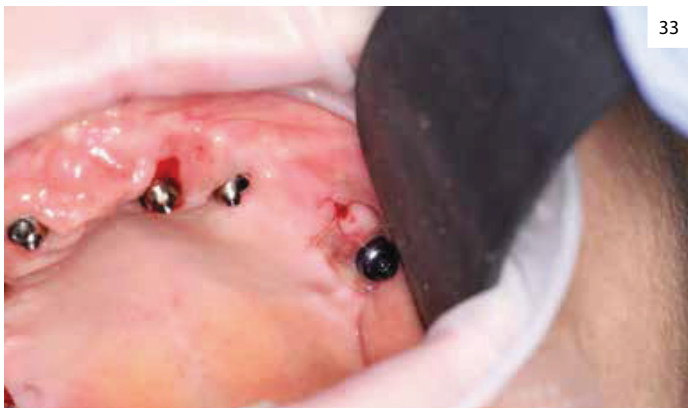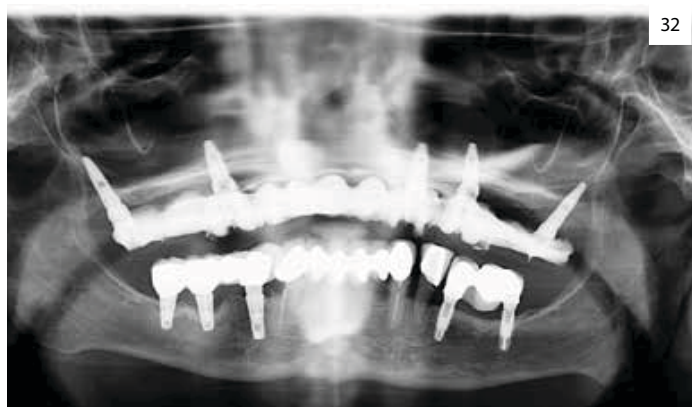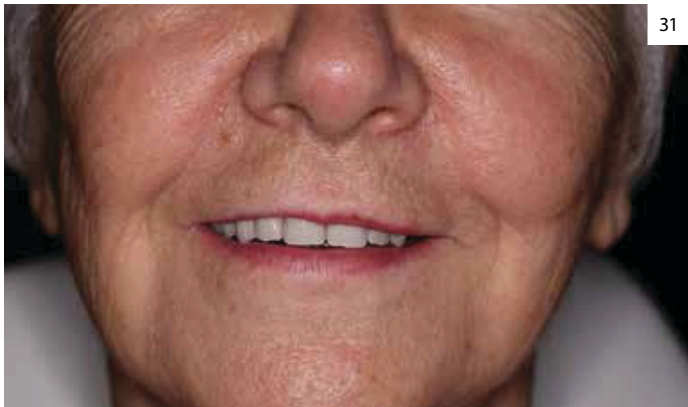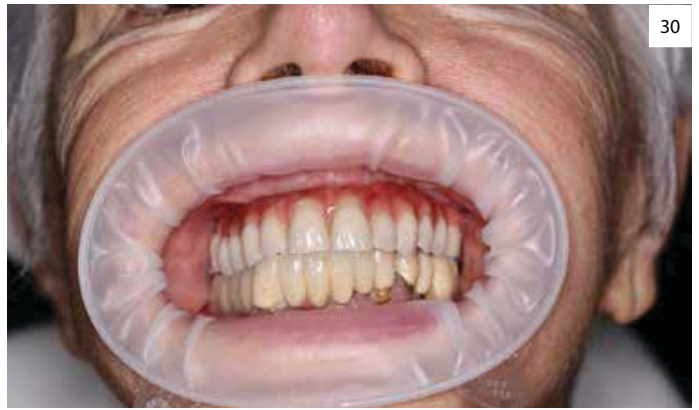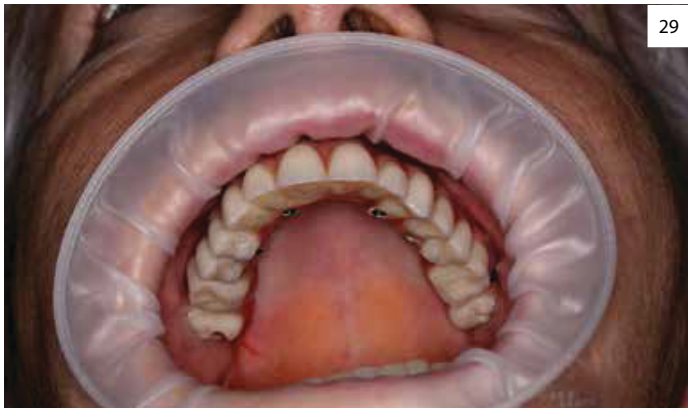placed in intimate contact with the palatal cortical to gain stability, seeking to use all the available bone height (photos 13-17). A symmetrical distribution of the implants and parallelism is calculated to allow a homogeneous distribution of the occlusal loads in the bone(26) (photo 17).

Once the receptor sites have been prepared, 4 Ziacom® ZinicMT® implants of 3.60 mm in diameter and 10 mm in length are introduced in anterior sectors, and 11.5 mm in length in posterior sectors (photos 16-17).

In this case, only the 4 implants in the anterior area are immediately loaded due to their adequate primary stability. The implants in the maxillary tuberosities will be submerged during an integration period of six months, and then proceed to their deferred loading, since they did not have the stability values necessary for immediate loading. In cases such as this, a combined load is chosen, offering the advantages of immediate loading in anterior area and reinforcing it with the deferred loading of posterior implants. The ISQ values and the patient's collaboration will be the determining factors to carry out the immediate loading. The implants are placed

with 35Ncm of insertion torque, always verifying the primary stability of the implants using Osstell® and obtaining ISQ values between 65 and 72 (photo 18). If an implant does not reach the recommended value for immediate loading, it will be loaded if the value is close to the recommended value. These implants with less stability integrate perfectly if a correct occlusion and occlusal load is established, which is achieved by adding experience to the splinting offered by the immediate prosthesis chosen, whose base is a titanium framework. Because occlusal loads are distributed over all implants, an implant that does not fulfil with the established ISQ entails a risk that could be assumed, since micromovement will be equal to or less than that of the rest of the implants (27-29).

To improve the stability of the peri-implant tissues, fundamental in immediate load treatments with multiple implants, transepithelial abutments are placed to correct the angulation of the definitive abutments (photos 19-20), facilitating not only the insertion of the prosthesis, but also its aesthetics. Following the "one abutment one time"(30) theory, these abutments will not be removed again, respec-



-ing the biological seal (photo 20). Intraoperative and before any regeneration, the impression abutments are placed (photo 20), making it easier to check the correct fit between them and the transepithelial abutments. It is then regenerated with a mixture of  $\beta$ -tricalcium phosphate(31), autologous bone recovered from the drilling of the implant bed and cut A-Prf membranes (photo 21), covering and protecting the grafts with resorbable T-Gen collagen membranes, which will seal the regenerated areas (photo 22). A-Prf membranes are placed on the collagen membranes to stimulate healing and vascularisation, which will

accelerate the regeneration of the surrounding tissues(32-34). The A-Prf membranes are placed by making an incision so that they can be fixed around the implants, sealing any dehiscence that may occur around them (photos 24-25). The wound is closed with 4/0 resorbable suture at vestibule base, an apical mattress technique to stabilise regeneration, reduces pressure and minimise flap movement(35). The incision is sutured with 4/0 nylon for primary closure (photo 26). Once the impressions have been taken, the facebow registration for mounting on the articulator, the bite and aesthetic records, and radiographs verification,

the prosthesis technicians manufacture, according to the previous study and designs, the screwed-retained hybrid prosthesis that will be placed 24 hours later.

The use of the facebow to record the three-dimensional position of the maxilla, as well as the recordings in centric and eccentric relation are of crucial importance (photo 28). There is a predisposition to avoid the articulator, but it is essential if the clinician wants to establish a correct occlusion and functionality of the prosthesis. This will have a crucial influence on the success of the treatment because the type and magnitude of loads on the implants and peri-implant tissues will be controlled from the beginning.

After 6 months of integration, several occlusal stability controls and integration control radiographs, the posterior implants will be released to place the intermediate abutments and add the distal extension to the hybrid prosthesis (photos 29-34). In addition, the prosthesis will be relined to compensate the gap created between the hybrid prosthesis and the soft tissue as a consequence of the hard and soft tissues remodelling in the maxilla. This ability to add and remove material at will, allows us to conform the emergency profiles to achieve a correct sealing of the soft tissue with the prosthesis, reducing waste retention, improving aesthetics and patient comfort (photos with 4 and with 6, and gum).

#### Conclusion

We have been able to show how over time the criteria of implantology have evolved. In terms of immediate loading, from the denial of Brånemark to today's recommendation, and these criteria will continue to evolve if the technology, materials and techniques that we have and will have at our disposal continue to do so. In this clinical case, the starting point has been a situation, in principle, not favourable to carrying out immediate load treatment, but which, thanks to experience and determination by part of the patient was successfully completed.

The accepted criteria should not always be considered strict in their application but as a guide to lead us to success in our treatments, adapting them to each case. Careful technique, enough clinical experience and adequate knowledge are fundamental to the success of the treatments.

#### Résumé

The studies and praxis of immediate loading have managed to situate this technique as a predictable practice in contemporary implantology, reaching a success rate of over 90% in the appropriate cases for its application.

Although there is still a significant prejudice to its exercise among a considerable spectrum of dental community, the successful resolution of complex cases with its use demonstrates not only its constant evolution, but also adds favourable positions to the technique. The main requirement is, in many cases, the ability to identify suitable cases for their application, whose number is increasing thanks to innovation in implants, regeneration materials and surgical and prosthetic techniques. The clinical case presented below will illustrate how

these factors, the patient's experience and commitment, as well as the correct application of immediate loading and optimal bone regeneration will be essential to successfully save an advanced periodontal state in a patient who has just undergone a serious oncological process.

---

#### Summary

The successful result of complex clinical cases for the use not only shows the continuous development but also sums favorable positions to this technique, although there is still a substantial prejudice about its exercise among a considerable spectrum of the Dental Community. The main requirement is, in many cases, the ability to identify suitable cases for application, whose number is increasing through innovation in implants, regeneration materials and surgical and prosthetic techniques. The clinical case presented below illustrates how these factors, the experience and commitment of the patient, as well as a correct application of the immediate load and an optimal bone regeneration will be the key to a successfully save an advanced periodontal state in a patient who has just suffered a serious oncological process.

**Bibliography**

- 1 Brånemark PI, Hansson BO, Adell R, Breine U, Lindström J, Hallen O, et al. Osseointegrated Implants in the treatment of the edentulous jaw. Experience from a 10-year period. *Scand J Plast Reconstr Surg Suppl.* 1977;16:1-132.
- 2 Ledermann PD. Stegprothetische Versorgung des zahnlosen Unterkiefers mit Hilfe von plasmabeschichteten Titan-schraubenimplantaten. *Dtsch Zahnärztl Z* 1979;34:907-11.
- 3 Schroeder A. The ITI hollow-cylinder implant. Internationales Team für orale Implantologie. *Schweiz Monatsschr Zahnmed* 1985;95:876-8.
- 4 Babbush CA, Kent JN, Miskle DJ. Titanium plasma-sprayed (TPS) screw implants for the reconstruction of the edentulous mandible. *J Oral Maxillofac Surg* 1986;44:274-82.
- 5 Buser DA, Schroeder A, Sutter F, Lang NP. The new concept of ITI hollow-cylinder and hollow-screw implants: Part 2. Clinical aspects, Indications, and early clinical results. *Int J Oral Maxillofac Implants* 1988;3:173-81.
- 6 Schnitman PA, Wöhrle PS, Rubenstein JE, DaSilva JD, Wang NH. Ten-years results for Brånemark Implants immediately loaded with fixed prostheses at Implant placement. *Int J Oral Maxillofac Implants* 1997;12:495- 503.
- 7 Aparicio C, Rangert B, Sennnerby L. (2003) Iediate/early loading of dental Implants: a report from the Sociedad Espanola de Implantes World Congress Consensus Meeting in Barcelona, Spain, 2002. *Clin Implant Dent Relat Res* 5:57-60.
- 8 Randow K, Ericsson I, Nilner K, Petersson A, Glantz PO. Immediate functional loading of Brånemark dental implants. An 18-month clinical follow-up study. *Clinical Oral Implants Research* 1999;10:8-15.
- 9 Ericsson I, Randow K, Nilner K, Petersson A. Early functional loading of Brånemark dental Implants: 5-year clinical follow-up study. *Clinical Implants Dentistry And Related Reserch* 2000;2:70-7.
- 10 Ibanez JC, Jalbout ZN. Iediate loading of osseotite Implants: 2-year results. *Implant Dent* 2002;11:128- 36.
- 11 Rungcharassaeng K, Lozada J, Kan JYK, Kim J, Campagni W, Muñoz C. Peri-Implant tissue response of immediate loaded, threaded, HA-coated Implants: 1-year results. *J Prosthet Dent* 2002;87:173-81.
- 12 Chiapasco M, Gatti C, Rossi E, Haefliger W, Markwalder TH. Implant-retained mandibular overdentures with Iediate loading. A retrospective multicenter study on 226 consecutive cases. *Clinical Oral Implants Research* 1997;8:48-57.
- 13 Ganeles J, Rosenberg J, Holt RL, Reichman LH. Iediate loading of Implants with fixed restorations in the completely edentulous mandible: report of 27 patients from a private practice. *Int J Oral Maxillofac Implants* 2001; 16:418-26.
- 14 Jaffin RA, Kumar A, Berman CL. Iediate loading of Implants in partially and fully edentulous jaws: a series of 27 cases reports. *J Periodontol* 2000;71: 833-8.
- 15 Chiapasco M, Abati S, Romeo E, Vogel G. Implant-retained mandibular overdentures with Brånemark System MKII Implants: a prospective comparative study between delayed and Iediate loading. *Int J Oral Maxillofac Implants* 2001;16:537-
- 16 Tarnow DP, Emthiaz S, Classi A. Iediate loading of threaded Implants at stage 1 surgery in edentulous arches: ten consecutive case reports with 1- to 5-year data. *Int J Oral Maxillofac Implants* 1997;12:319-24.
- 17 Schnitman PA, Wöhrle PS, Rubenstein JE, DaSilva JD, Wang NH. Ten-years results for Brånemark Implants immediately loaded with fixed prostheses at Implant placement. *Int J Oral Maxillofac Implants* 1997;12:495- 503.
- 18 Grunder U, Polizzi G, Goene R, Hatano N, Henry P, Jackson WJ, et al. A 3-year prospective multicenter follow-up report on the Iediate and delayed-Iediate placement of Implants. *Int J Oral Maxillofac Implants* 1999;14:210-6.
- 19 Chaushu G, Chaushu E, Tzohar A, Dayan D. Immediate loading of single-tooth Implants: Iediate versus non-Iediate Implantation. A clinical report. *Int J Oral Maxillofac Implants* 2001;16:267-72.
- 20 Malo P, Rangert B, Dvarsater L. Iediate function of Brånemark Implants in the esthetic zone: a retrospective clinical study with 6 months to 4 years of follow-up. *Clin Implant Dent Relat Res* 2000;2:138-46.
- 21 Grunder U. Iediate functional loading of Iediate Implants in edentulous arches: two-year results. *Int J Periodontics Restorative Dent* 2001; 21:545-51.
- 22 Colomina L. Immediate loading of implant-fixed mandibular prostheses: a prospective 18-month follow-up clinical study. Preliminary report. *Implant Dent* 2001;10:23-9.
- 23 Calvo JL, Saez R, Ferrer V, Moreno A. Iediate anterior implant placement and early loading by provisional acrylic crowns: a prospective study after a one-year follow-up period. *J Ir Dent Assoc* 2002;48:43-9.
- 24 Aires I, Berger J. Iediate placement in extraction sites followed by Iediate loading: a pilot study and case presentation. *Implant Dent* 2002; 11:87-94.
- 25 Gatti C, Haefliger W, Chiapasco M. Implant-retained mandibular overdentures with Iediate loading: A prospective study of ITI Implants. *Int J Oral Maxillofac Implants* 2000;15:383-8.
- 26 Francetti L, Cavalli N, Villa T, La Barbera L, Taschieri S, Corbella S, Del Fabbro M. Biomechanical in vitro evaluation of two full-arch rehabilitations supported by four or five Implants. *Int J Oral Maxillofac Implants.* 2015 Mar-Apr;30(2):419-26. doi: 10.11607/jomi.3767.
- 27 Staedt H1, Palarie V, Staedt A, Wolf JM, Lehmann KM, Ottl P, Käerer PW. Primary Stability of Cylindrical and Conical Dental Implants in Relation to Insertion Torque-A Comparative Ex Vivo Evaluation. *Implant Dent.* 2017 Apr;26(2):250-255. doi: 10.1097/ID.0000000000000531.
- 28 Lages F51, Willya Douglas-de-Oliveira D1, Ibelli GS2, Assaf F2, Queiroz TP2, Costa FO1. Relationship between implant stability on the abutment and platform level by means of resonance frequency analysis: A cross-sectional study. *PLoS One.* 2017 Jul 24;12(7):e0181873. doi: 10.1371/journal.pone.0181873. eCollection 2017.
- 29 Akoglan M1, Tatli U2, Kurtoglu C1, Salmov F2, Kırkıç M2. Effects of different loading protocols on the secondary stability and peri-implant bone density of the single Implants in the posterior maxilla. *Clin Implant Dent Relat Res.* 2017 Aug;19(4):624-631. doi: 10.1111/cid.12492. Epub 2017 May 10.
- 30 Marco Degidi I, Diego Nardi I, Adriano Plattelli One abutment at one time: non-removal of an Iediate abutment and its effect on bone healing around subcrestal tapered Implants. 24 February 2011. DOI: 10.1111/j.1600-0501.2010.02111.x
- 31 Velasco Ortega e Pato Mourel J García Méndez A, Medel Soteras R. López Frías J. Clinical and histologic study of beta-tricalcium phosphate in sinus floor elevation. *Av Periodon Implantol.* 2008; 20(3): 147-154.
- 32 Pirpir C1, Yilmaz O2, Candirli C1, Balaban E1. Evaluation of effectiveness of concentrated growth factor on osseointegration. *Int J Implant Dent.* 2017 Dec;3(1):7. doi: 10.1186/s40729-017-0069-3. Epub 2017 Mar 3.
- 33 Tadanori Maoto Amanda Jiang Elisabeth Jiang Akiko Maoto Platelet rich plasma extract promotes angiogenesis through the angio-poleitin1-Tie2 pathway. *Microvascular research.* 2013 Sept. 15-24
- 34 Michael O. Schär José Díaz-Romero, Sandro Kohl Matthias A., Zumstein Dobrila Nesic Platelet-rich Concentrates Differentially Release Growth Factors and Induce Cell Migration in Vitro *Clinical Orthopaedics and Related Research*® May 2015, Volume 473, Issue 5, pp 1635–1643.
- 35 Akiko Maoto, Kip M. Connor, Tadanori Maoto, ChongWing Yung, Dongeun Huh, Christopher M. Aderman, Gustavo Mostoslavsky, Lois E. H. Smith, and Donald E. Ingber A mechanosensitive transcriptional mechanism that controls angiogenesis *Nature.* 2009 February 26; 457(7233): 1103–1108. doi:10.1038/nature07765.



# GACETA DENTAL

Date: November 2016

Page: 168-172 N° 285

Country: Spain

Article name: UPPER ANTERIOR ANATOMICAL BRIDGE BY  
RADIOLOGICAL IMPRESSION

Products: OIN®

Dentist: Dr. Luis Sepúlveda Salas





### Dr Luis Sepúlveda Salas

Bachelor of Dental Surgery by the University of Chile. Oral surgeon by the University of Chile.  
Degree in Dentistry. European University of Madrid. Specialist in Oral Surgery and Orthodontics (Madrid).

### Juan Carlos Palma

Degree in Dental Prosthesis. CES Ramón y Cajal of Cordoba. Specialist in Dental CAD/CAM Technology.  
Technical Director at Ziacor CAD/CAM Milling Centre (Madrid).

## UPPER ANTERIOR ANATOMICAL BRIDGE BY RADIOLOGICAL IMPRESSION

### RESUMEN

La clave para el éxito del tratamiento con implantes en la zona anterior es una relación armoniosa entre la restauración implantológica y los dientes naturales adyacentes. Para lograr este objetivo, los implantes deben ser planificados e implantados en concordancia conceptual, como la fase quirúrgica de una

solución protésica óptimamente visualizada, como es descrito por Garber y Belser en los tres conceptos de «restauración manejada en la planificación del tratamiento con implantes».

Este enfoque exige una planificación del tratamiento considerando las tres dimensiones obvias, y el factor temporal, seguido por la colocación de los implantes en posiciones óptimas para la función y la estética. La evaluación inicial en 3D de las posiciones ideales debe incluir una planificación para el aumento o preservación de los tejidos óseos y blandos existentes (1-3).

En la actualidad se dispone de materiales cerámicos con propiedades mecánicas mejoradas, comparables a las restauraciones de metalcerámicas, aparte de sus ventajas por las propiedades ópticas y de biocompatibilidad apreciadas (4). Por razones estéticas, la demanda de restauraciones implantosoportadas compuestas de estructuras y coronas totalmente cerámicas ha aumentado significativamente. Las cerámicas de óxido de circonio son usadas en esos casos como primera indicación para confeccionar los aditamentos para implantes dentales, dado que han mejorado su resistencia y su compatibilidad con los tejidos blandos.

La combinación de una estructura cerámica y una corona totalmente cerámica mejora la transmisión de la luz a través del tejido periimplantario (5, 6).

La tecnología CAD/CAM ha demostrado su capacidad de fabricar restauraciones protéticas con la calidad superior a las alternativas fabricadas con técnicas convencionales (7, 8). En situaciones de alta demanda estética las soluciones cerámicas personalizadas por CAD/CAM están indicadas.

---

**ZIRCONIUM FRAMEWORKS ARE A USEFUL OPTION FOR RESTORATION IN THE ANTEROSUPERIOR SECTOR AS THEY OFFER GOOD AESTHETICS AND RESISTANCE TO HIGH OCCLUSAL LOADS.**

---

**Palabras clave:** Prótesis, implantes dentales, prótesis removibles, prótesis fija, rehabilitación dental, circonio, caso clínico, hueso, conexión hexagonal externa, PEEK, osteointegración.

### ABSTRACT

The clue to the success of the treatment with implants in the anterior region is a harmonious relationship between the restoration implant supported and the remaining natural teeth. To achieve this goal, the implants should be conceptually planned and placed as an extension of a restoration optimally displayed, as described by Garber and Belser in 3 concepts of «Restoration-driven implant placement with restoration-generated site development». This approach requires a minimum treatment planning 3 dimensions, followed by the placement of implants in optimal positions for the function and aesthetics. The initial assessment in 3D's potential site, must include planning for the increase or preservation of existing bone and gingival tissues (1-3).

Currently we have available ceramic materials with improved mechanical properties similar to metal restorations ceramics, apart from the optical properties and biocompatibility already known (4). For aesthetic reasons, the demand by restorations implant supported composed of structures and crowns completely ceramics, has increased in the last times. The ceramics of oxide of zirconium are used for making attachments for implants dental, now that they have improved its resistance and its compatibility with tissues soft.

The combination of a ceramic structure and an all-ceramic crown improves the transmission of light through the peri implant tissue.

CAD/CAM technology has shown its ability to manufacture prosthetic restorations with similar quality to the alternatives made with conventional techniques (5, 6).

In situations of high demand for aesthetic reasons are indicated ceramics solutions customized by CAD/CAM (7, 8).

**Keywords:** Prosthesis, dental implants, removable prosthesis, fixed prosthesis, dental rehabilitation, zirconium, clinical case , bone , hexagonal external connection, PEEK , osseointegration.

**CLINICAL CASE**

- Patient: 28-year-old male.
- Medical history:
  - Smoker.
  - No medical pathology or contributing medical history.
- Reason for consultation: Absence of pieces 12 to 23
- Treatment plan:
  - Placement of three ZIACOM® RP implants at level 12-21-23.
  - Clinical control every 15 days.
  - Prosthetic restoration 3 months after placement, after adaptation of the soft tissue to the provisional prosthesis made with the patient's removable acrylic prosthesis and provisional ZIACOM® PEEK abutments.

**Initial situation**

The loss or absence of pieces in the upper anterior sector always entails a series of changes both in the gingival tissue and in the bone tissue, leading to unfavourable aesthetic situations.

The patient came to the consultation due to the absence of teeth 11, 12, 21, 22 and 23. In this case, the patient was provided with a removable acrylic prosthesis, which restored the aforementioned pieces. But the discomfort of it made him resort to the most aesthetic and functional option, a direct fixed prosthesis to implant.

In this clinical case we will expose the accomplishment of an upper anterior restoration made in direct zirconium to three ZIACOM® standard external hexagonal connection implants.

**Procedure**

First, a clinical study of the patient is performed to evaluate the quantity and quality of available tissues and determine the best prosthetic solution (**Figure 1**).

After this study, proceed to the surgical procedure. In this case, three standard ZIACOM® external hexagonal connection implants are placed in positions 12, 21 and 23. After performing the osteotomy, proceed to check the axis of the implants using the paralleling pins (**Figure 2**).

Then the insertion of the implants begins (**Figures 3 and 4**). Using an Ostell® device (**Figure 5**), an ISQ value, indicative of the adequate primary stability for immediate provisionalisation, is obtained.

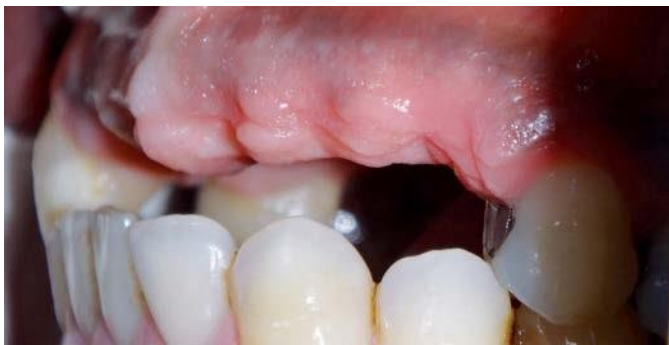

Figure1.

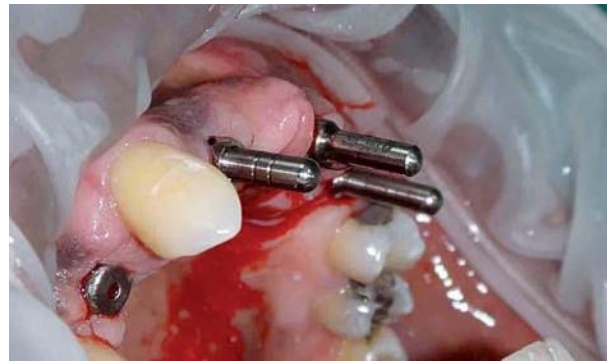

Figure2.

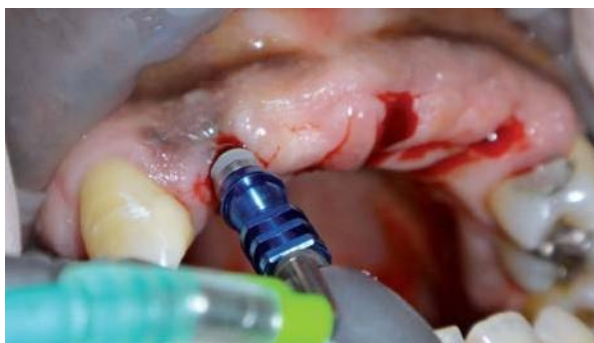

Figure3.

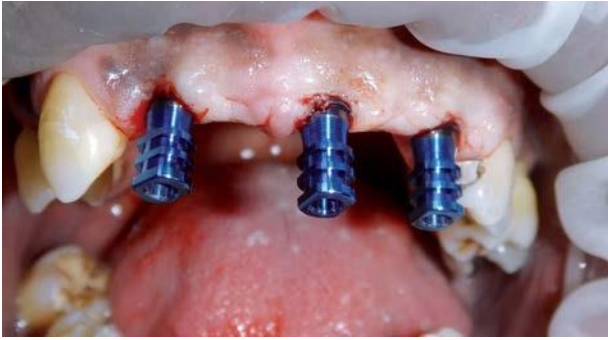


Figure 4.

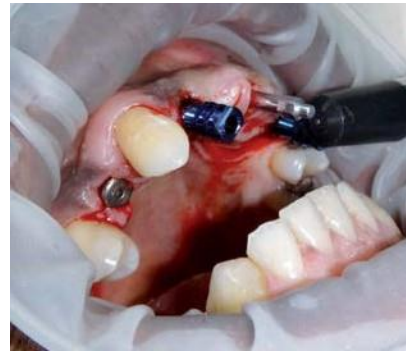

Figure 5.

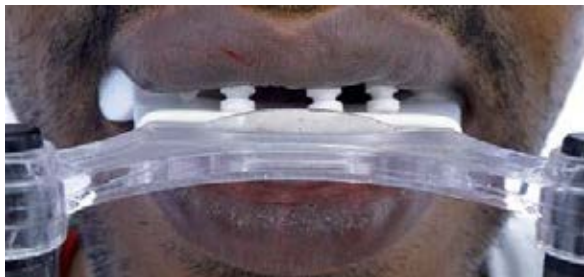

Figure 6.

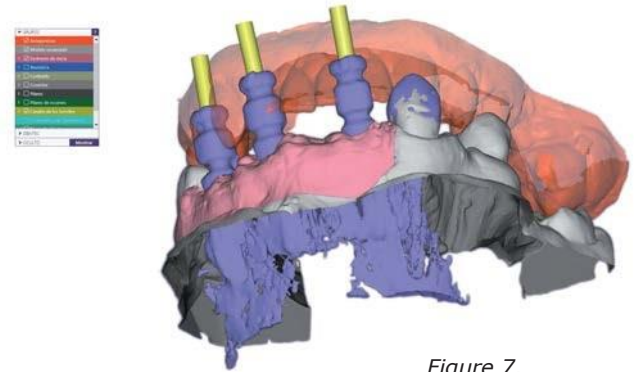


Figure 7.

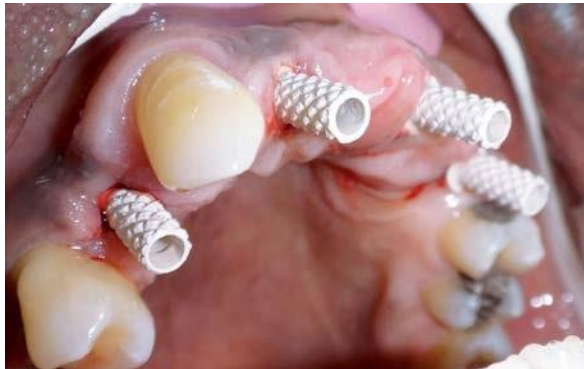

Figure 8.

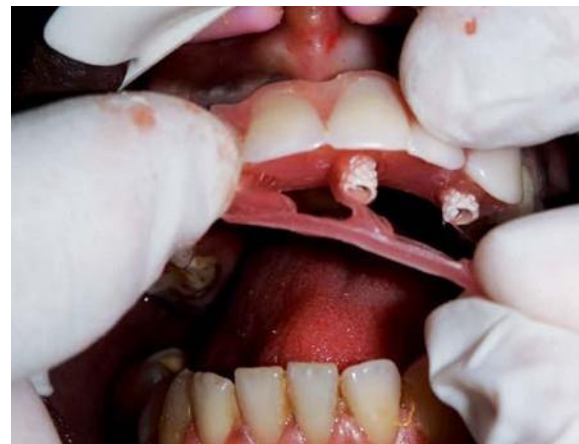

Figure 9.

Next, screw to the implants, manually, with an approximate torque of 10 Ncm, some PEEK Radiopaque scanning abutments (Scanbodies), and perform a 3D CAT scan of the patient (**Figure 6**).

The images obtained (in DICOM files) are processed and converted into the universal format ".stl", used by the CAD design software.

Thanks to the file generated, and through CAD/CAM technology, we can obtain the exact position of the implants,

achieving an intraoral passive adjustment of 10 $\mu$ . Make a pick-up technique impression with heavy and light body to the framework in order to obtain a register of the soft tissues, since these do not appear in the images of the CBCT (**Figure 7**). In the next phase of the treatment, three provisional ZIACOM® PEEK abutments are placed, adapted to the patient's provisional prosthesis, in order to shape the tissues, define the emergence profile and thus achieve a more natural aesthetic result (**Figures 8 and 9**).

At Ziacor® CAD/CAM centre, the upper anterior Veneer restoration was designed and manufactured with monolithic anatomical zirconium crowns with vestibular reduction for ceramic characterisation (9-12). Aesthetic results of natural mimicry are obtained (Figures 10-12).

### CONCLUSION

Zirconium frameworks are a useful option for restoration in the upper anterior sector as they offer good aesthetics and resistance to high occlusal loads. ●

### Thanks

To the Dr Sepúlveda Dental Specialities Centre (Madrid); OBS Technique: Orquín Dental Centre (Aracena, Huelva); Ceramist: Farley Henao and by the collaboration of Dr Jorge Sánchez Aguado.

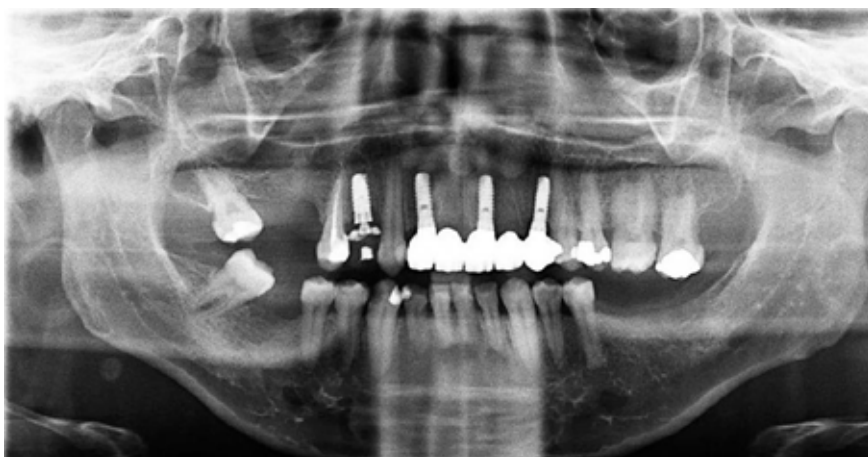


Figure10.

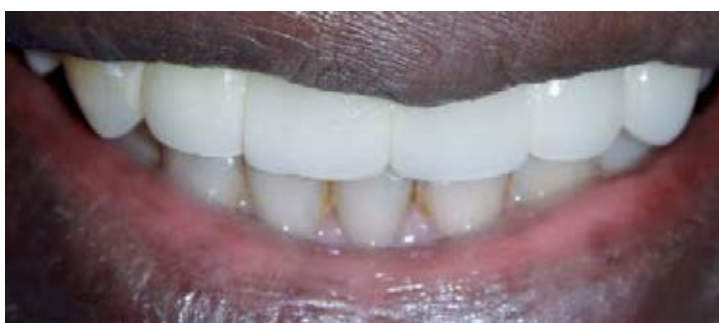

Figure11.

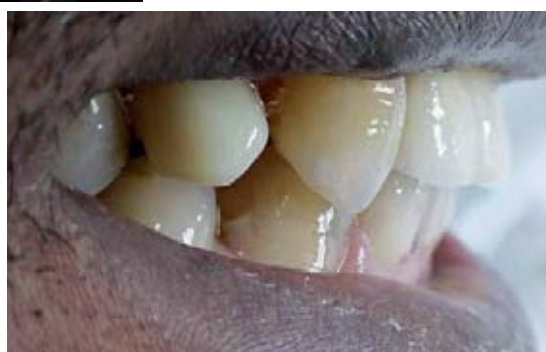

Figure12.

### BIBLIOGRAPHY

1. Huamani-Chavez A, Balarezo-Razzeto JA2, Matta-Morales C2, Cca- huana-Vásquez V3. Customised abutments and ceramic systems with CAD-CAM technology in aesthetic management of the anterior sector on supported implant restorations. Case reports. Rev Estomatol Herediana. 2012; 22 (2): 100-108.
2. Garber DA, Belser UC. Restoration-driven implant placement with restoration-generated site development. Compend Contin Educ Dent. 1995; 16 (8): 796, 798-802, 804.
3. Funato A, Salama MA, Ishikawa T, Garber DA, Salama H. Timing, positioning, and sequential staging in aesthetic implant therapy: a four-dimensional perspective. Int J Periodontics Restorative Dent. 2007; 27 (4): 313-23.
4. Kohal RJ, Att W, Bächle M, Butz F. Ceramic abutments and ceramic oral implants. An update. UPeriodontol 2000. 2008; 47: 224-43.
5. Bindl A. Enhanced light transmission. Australasian Dental Practice. 2010; 21 (5): 184-186.
6. O'Keefe KL, Pease PL, Herrin HK. Variables affecting the spectral transmittance of light through porcelain veneer samples. J Prosthet Dent. 1991; 66 (4): 434-8.
7. Strub JR, Rekow ED, Witkowski S. Computer-aided design and fabrication of dental restorations: current systems and future possibilities. J Am Dent Assoc. 2006; 137 (9): 1289-96.
8. Sailer I, Zembic A, Jung RE, Hämmerle CH, Mattioli A. Single-tooth implant reconstructions: aesthetic factors influencing the decision between titanium and zirconia abutments in anterior regions. Eur J Esthet Dent. 2007; 2 (3): 296-310.
9. Chichoyan F, Vanheusden A. Bonded porcelain veneers. Rev Belge Med Dent. 2006; 61 (1): 47-64.
10. Sced IR, McLean JW. A survey of the sizes of full porcelain veneer crown preparations. Br Dent J. 1987; 163 (11): 345-6.10.
11. Gage JP. Rationale for bevelled should veneer crown preparations. Aust Dent J. 1977; 22 (6): 432-5.
12. Shillingburg HT Jr. Conservative preparations for cast restorations. Dent Clin North Am. 1976; 20 (2): 259-71.



# AVANCES

EN PERIODONCIA E IMPLANTOLOGÍA ORAL

Date: April 2014

Page: 39-44 Volumen 26 nº 1

Country: Spain

Article name: FACTORS INFLUENCING STABILITY.  
DIAMETER AND LENGTH

Products: OIN®

Dentists: CERVANTES HARO N  
ENCABO DURÁN MJ  
CALDERÍN PÉREZ S  
ARAGONESES LAMAS JM

# Factores que influyen en el coeficiente de estabilidad: Diámetro y longitud

## *Factors influencing stability. Diameter and length*

**CERVANTES HARO N\***  
**ENCABO DURÁN MJ\*\***  
**CALDERÍN PÉREZ S\*\*\***  
**ARAGONESES LAMAS JM\*\*\*\***

Cervantes Haro N, Encabo Durán MJ, Calderín Pérez S, Aragonese Lamas JM. *Factores que influyen en el coeficiente de estabilidad: Diameter and length* *Av Periodon Implantol.* 2014; 26, 1: 39-44.

### RESUMEN

**Objetivos:** Determinar si el diámetro y la longitud de los implantes dentales son factores determinantes de la estabilidad primaria.

**Material y métodos:** Se colocaron 17 implantes unitarios OIN de la casa Osseolife® Implant System de diámetros 3,75, 4,25 y 5,0 mm y longitudes de 10 y 11,5 mm. El coeficiente de estabilidad fue medido mediante el Osstell Mentor® durante la cirugía de colocación. Los resultados obtenidos fueron comparados en cuanto al diámetro y la longitud con el estadístico para muestras independientes *t* de Student.

**Resultados:** El coeficiente de estabilidad mayor fue para los implantes de diámetro estrecho (3,75 mm) y cortos (10 mm) con un ISQ de 75,5 y 76,0 respectivamente. Para los otros diámetros y longitud los resultados fueron: Para los implantes de 4,25 mm y 5,0 mm obtuvieron un ISQ de 74,7, y 74,33, respectivamente, y para el implante denominado largo con longitud de 11,5 mm el coeficiente de estabilidad fue de 70,85. En ambos parámetros, objeto de estudio, no se encontraron diferencias estadísticamente significativas con  $p > 0,05$ .

**Conclusiones:** Tanto la longitud como el diámetro no son factores determinantes del coeficiente de estabilidad primaria.

**PALABRAS CLAVE:** Implantes dentales, estabilidad, diámetro, longitud.

### SUMMARY

**Objectives:** To determine if the diameter and length of the dental implants are determinants of primary stability.

**Materials and methods:** Seventeen (17) single implants OIN Osseolife® Implant System of diameters 3.75, 4.25 and 5.0 mm and lengths of 10 and 11.5 mm were placed. The stability coefficient was measured using the Mentor® Osstell during the surgery. The results were compared in terms of diameter and length with the statistical analysis for independent samples *t* test.

**Results:** The stability coefficient was highest for small diameter implants (3.75 mm) and short ones (10 mm) with an ISQ of 75.5 and 76.00 respectively. For other diameters and length, implants of 4.25 mm and 5.0 mm obtained an ISQ of 74.7, and 74.33 respectively and for the considered a long implant

\* Doctor of Dentistry. Professor of the Master of Surgery, Implantology and Periodontics at the University of Alcalá and the University of Mississippi.

\*\* Professor of the Master of Surgery, Implantology and Periodontics at the University of Alcalá and the University of Mississippi.

\*\*\* Student of the Master of Surgery, Implantology and Periodontics at the University of Alcalá and the University of Mississippi.

\*\*\*\* Doctor of Dentistry. Director of the Master of Surgery, Implantology and Periodontics at the University of Alcalá and the University of Mississippi. Director of the European University of Madrid.

(11.5 mm length) stability coefficient was 70.85. In both studied parameters, there were no statistically significant differences with  $p > 0.05$ .

*Conclusions:* Both the length and the diameter are not determinants of primary stability coefficient.

**KEY WORDS:** Dental implants, stability, diameter, length.

**Receipt date:** 28 January 2013.

**Acceptance date:** 29 April 2013.

## **PREAMBLE**

The loss of a tooth can produce problems in some patients, of the functional type as the difficulty to chew or psychological due to the aesthetic alterations (1). Oral restoration with dental implants has been a treatment for replacing missing teeth for more than two decades (2). Dental implants were initially a failure due to the non-biocompatibility of the materials, until 1965 when Brånemark achieved osseointegration of titanium to bone (3). The technique described by Brånemark has been used as a standardised procedure since 1971. The original implant was 10 mm long and 3.75 mm in diameter, with a design like that used today (4). The protocol proposed by Brånemark in 1969 was a two-stage surgical technique, where the implant was placed in the bone and subsequently covered by the oral mucosa, for 6 months in the upper jaw and 4 months in the lower jaw, thus preventing the implants from being functionally loaded or having a chance of being contaminated (1). Although this protocol is still the most widespread, the protocol known as immediate loading (5) is currently also used, allowing clinicians to shorten treatment times, thus improving the patient's life quality, not only in chewing function but also aesthetics (6, 7).

One of the clinician's main concerns is to know at what point of treatment the implant can be connected to the prosthetic abutment for prosthetic restoration, which can be determined by the stability of the implant. We can define primary stability as the mechanical bond between bone and implant at the time of implant placement. (8, 9); and secondary stability is that which occurs once the osseointegration process is completed (10). Different methods have been used to measure stability, such as insertion torque (11, 12), radiographical methods (12), histological analysis (13), Periotest® (14), among others. All these methods have different limitations, either because they are aggressive techniques for

patients, or because they are not reproducible or simply relegated to the experimental laboratory. Other study methods have been investigated for years until Meredith, in 1996, (15, 16) described Resonance Frequency Analysis (RFA). This method allows studying the stability of the dental implant at different times of bone healing, the results obtained being reproducible intraoperator and interoperator. This study method is based on frequency analysis, which consists of an L-shaped transducer (1) that is screwed to the implant perpendicular to the bone crest (17). This transducer is stimulated by a sinusoid signal with a frequency of 5 to 10 KHz. (1, 15, 18), this signal is going to be translated by frequency analysis. The results obtained are represented by the implant stability coefficient (ISQ) with an implant mobility range from 0 to 100, being 100 the most stable (9, 19, 20).

At present, the Osstell Mentor® has been developed which, unlike the RFA, the transducer is not connected by cable, but rather emits an electromagnetic signal to a device manually screwed to the implant, which is called Smartpeg® (21).

The objective of this study is to determine whether length and diameter are determining factors in the primary stability coefficient of dental implants.

## **MATERIAL AND METHODS**

The present study was developed in the Master of Implantology, Periodontics and Surgery of the University of Alcalá given at the University of Mississippi.

### **Patient Selection**

This study was conducted in 17 patients with an absent tooth, of whom 10 were women and



7 were men between the ages of 30 and 70. All patients were given informed consent to sign before the study, orthopantomography for first assessment and basic periodontal therapy for all patients who needed it with hygiene instructions.

### **Inclusion criteria**

- Adult patients.
- No systemic pathology.
- Adequate quantity and quality of bone for good primary ability.
- Periodontally stable patients.
- Non-smoking patients.
- ASA patients types I and II.
- Implant crown ratio no greater than 1:1.

### **Exclusion criteria**

- Unrealistic expectations.
- Autoimmune, psychiatric diseases.
- Patients with overdentures.
- Patients with extractions performed 3 months or less prior to surgery.

### **Surgical procedure**

All patients were prescribed antibiotic prophylaxis, 2 g amoxicillin (600 mg clindamycin to penicillin allergy) 1 hour before surgery. The implants used were Osseolife® Implant System OIN 3.75, 4.25 and 5 mm in diameter and lengths of 10 and 11.5 mm. The osteotomy and placement of the implants was done according to the protocol established by the commercial company. Once the entire implant has been inserted into the bone site, the stability coefficient is measured. Once measured, the cover screw is placed and sutured with 3/0 silk from Aragó®. For the post-surgical treatment, Amoxicillin 750 mg or Clindamycin 300 mg, 3 daily doses for one week and Ibuprofen 600 mg were prescribed to control pain and inflammation. In addition, the post-surgical rules and hygiene techniques were explained. Seven days after surgery, patients were scheduled for suture removal.

### **Data collection**

The collection was done once the implant was placed in the osteotomy and just before the placement of the cover screw. In order to record the primary stability coefficient,

the SmartPeg® is screwed to the implant manually with the help of the mount with 10 N torque, which is the one recommended by Osstell®. Once the part is screwed on, the Osstell Mentor® is taken with the aerial perpendicular to the SmartPeg® and from the four possible orientations, vestibular, lingual, mesial and distal, wait for it to emit a continuous beep, which indicates that the reading has finished, the result appearing on the Osstell Mentor® LED screen. Once the measurement is finished, the SmartPeg® is removed from the implant with the mount.

### **STATISTICAL ANALYSIS**

The SPSS® software was used for the statistical analysis and for the comparative study the Student t test was applied for independent samples with a significance level of 95%.

### **RESULTS**

A total of 17 implants were placed of which 4 were narrow 3.75 mm (Oe) implants, 9 medium 4.25 mm (Om) implants and 3 wide 5 mm (Oa) implants. In terms of length distribution, 10 implants had 10 mm (Oc) and 7 implants had a length of 11.5 mm (Ol). The results obtained in this study according to diameter are the following: for Oe, Om, Oa implants, a stability coefficient of 75.5, 74.7, 74.33 ISQ was obtained, respectively, and, if the length is referred to, the average obtained for Oc implants, Ol is 76.70 and 70.85 ISQ, respectively, being the short implant of 10 mm the one that obtained the highest stability coefficient (Figure 1). The means standard deviation is shown in Table 1.

When comparing the diameters between each other, no statistically significant differences were obtained with  $p > 0.05$  and in the study group where the two implant lengths were compared, no statistically significant differences were found with  $p = 0.116$ .

### **DISCUSSION**

Since the beginning of dental implantology, as is now known described by Brånemark in 1967 (22, 23), attempts have been made to predict the success of implants. At present, due to the demands of both

TABLE 1.- RESULTS FROM THE DIFFERENT STUDY GROUPS						
	Average	Lower limit	Upper limit	Standard deviation	Stand ard error	Median
Oe	75.5000	65.3591	83.6409	5.0745	2.8723	73.0000
Om	74.7000	68.2217	81.1783	9.0560	2.8638	76.0000
Oa	74.3333	55.6885	92.9782	7.5055	4.3333	74.0000
Oc	76.7000	72.6667	80.7333	5.6382	1.7829	77.0000
OI	70.8571	62.6468	79.0674	8.8775	3.3554	72.0000

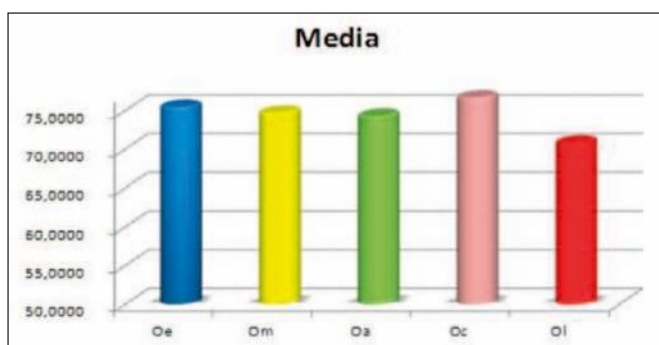


Fig. 1: Bar graph representing the averages in ISQ units.

professionals and patients, treatment times have been shortened. The need to know the state of the implant in relation to the bone has led to the search for methods to assess it. In addition, they allow us to know whether an implant is suitable for loading at the time of surgery (24), as it is increasingly common to perform immediate loading, leaving the protocol described by Brånemark relegated to cases where there are large bone defects or need for regeneration of soft tissue.

The reason for this study is to know which characteristics of the implants affect the stability of the implant, such as length and diameter.

The need to measure implant stability led to the comparison of different types of methods, such as Yoshihiro Ito et al.(12) in 2008, which compared three study methods: Insertion torque, Periotest® and RFA. It is also important when using a measuring instrument that the results obtained are reproducible both intraoperator and between operators, therefore Brouwers et al. (25) published a study with positive results at that point,

about the Ostell Mentor. Due to the cost of the Ostell Mentor, Degidi et al. (26) carried out a comparative study between the manual perception of implant stability at the time of implant placement by an experienced clinician and the actual measurement provided by the Ostell Mentor, obtaining significant differences between the results obtained between the stability perceived by the clinician and that obtained by the Ostell, reaching the conclusion that no matter how the experienced the clinician is, this perception varies between individuals, therefore it was determined that the use of the Ostell Mentor reproduces with greater reliability the real implant stability.

Diameter is one of the parameters that can determine the stability of implants. In the results obtained in this study, when comparing the three diameters, it has been found that there are no statistically significant differences, being the implant with the smallest diameter the one with the highest stability coefficient, not coinciding with what was published by Araceli Bonarat et al. (27) and Simunek et al. (10) which did obtain statistically significant differences in diameter, being the stability greater in the implants with the largest diameter. However, authors such as Huwiler et al. (28) also found no significant differences between the different diameters, as published by Bischof (29). With respect to length, no statistically significant differences were found, obtaining the highest stability coefficient for the shortest implant, coinciding with the studies published by Mashiko (9), Mihoko et al (22) and Payam et al (30). Similarly, Araceli Bonarat, in a study comparing implants of different lengths, did not obtain statistically significant differences, the primary stability being greater for the short implant. On the contrary, authors such as Stephen et al.(31) and Barewal et al. (3) obtained less stability in short implants,

but they coincide with this study because they did not find statistically significant differences between the different lengths, nor did Ersanli (16), Brochu et al. (32) and Calvo et al. (33) when they studied different parameters, including length, obtained a higher coefficient of stability in the implant of 10 mm than in 13 mm implants, and the result was not significant either.

## CONCLUSIONS

After the study carried out, it can be concluded:

1. The diameter is not a determining factor of the stability coefficient.
2. The length does not influence the stability coefficient.
3. The use of so-called wide implants does not imply that the stability results are higher than in narrow implants.
4. The greater length, the lower the stability coefficient.

## BIBLIOGRAPHY

- 1 Da Cunha HA, Francischon CE, Filho HN, de Oliveira RC. A Comparison Between Cutting Torque and Resonance Frequency in the Assessment of Primary Stability and Final Torque Capacity of Standard and TiUnite Single-Tooth Implants Under Immediate Loading. *Int J Oral Maxillofac Implants* 2004;19(4):578-85.
- 2 S, ençimen M GA, Özen J, Dergin C, Okçu KM, Ayyildiz S, Altug HA. Early Detection of Alterations in the Resonance Frequency Assessment of Oral Implant Stability on Various Bone Types: A Clinical Study. *J Oral Implantol* 2011;37(4):411-9.
- 3 Barewal RM, Meredith N, Cochran DL. Resonance frequency measurement of implant stability in vivo on implants with a sandblasted and acid-etched surface. *The Int J Oral Maxillofac Implants* 2003;18:641-51.
- 4 Friberg B, Grondahl K, Lekholm U. A New Self-Tapping Brånemark Implant: Clinical and Radiographic Evaluation. *Int J Oral Maxillofac Implants* 1992;7:80-5.
- 5 Aparicio C, Rangert B, Sennerby L. Immediate/early loading of dental implants: A report from the Sociedad Española de Implantes World Congress consensus meeting in Barcelona, Spain 2002. *Clin Implant Dent Relat Res* 2002;5:57-60.
- 6 Anitua E, et al. Clinical Outcome of Immediately Loaded Dental Implants Bioactivated With Plasma Rich in Growth Factors: A 5-Year Retrospective Study. *J Periodontol* 2008; 79(7):1168-76.
- 7 Cannizzaro G, Leone M, Espósito M. Immediate Functional Loading of Implants Placed with Flapless Surgery in the Edentulous Maxilla: 1-year Follow-up of a Single Cohort Study. *Int J Oral Maxillofac Implants* 2007;22:87- 95.
- 8 Abrahamsson I, Linder E, Lang NP. Implant stability in relation to osseointegration: an experimental study in the Labrador dog. *Clin Oral Implants Res* 2009;20(3): 313-8.
- 9 Yamaguchi M, Xu H, Shimizu Y, Hatano N, Ooya K. Resonance frequency analysis of long-term implant success in the posterior partially edentulous mandible. *Quintessence Int* 2008;39(3):121-5.
- 10 Simunek A, Strnad J, Kopecka D, Brazda T, Pilathadka S, Chauhan R, Slezak R. Changes in Stability After Healing of Immediately Loaded Dental Implants. *Int J Oral Maxillofac Implants* 2010;25(6):1085-92.
- 11 Cehreli MC, Kökat AM, Comert A, Akkocaoglu M, Tekdemir I, Akca K. Implant stability and bone density: assessment of correlation in fresh cadavers using conventional and osteotome implant sockets. *Clin Oral Implants Res* 2009;20(10):1163-9.
- 12 Ito Y, Sato D, Yoneda S, Ito D, Kondo H, Kasugai S. Relevance of resonance frequency analysis to evaluate dental implant stability: simulation and histomorphometrical animal experiments. *Clin Oral Implants Res* 2008; 19(1):9-14.
- 13 Johansson C, Albrektsson T. Integration of Screw Implants in the Rabbit: A 1-yr Follow-up of Removal Torque of Titanium Implants. *JOMI* 1987: 69-75.
- 14 Stein AE, McGlincy EA, Johnston WM, Larsen PE. Effects of Implant Design and Surface Roughness on Crestal Bone and Soft Tissue Levels in the Esthetic Zone. *Int J Oral Maxillofac Implants* 2009;24(5):910-9.
- 15 Iachmann S, Jäger B, Axmann D, Gómez-Román G, Groten M, Weber H. Resonance frequency analysis and damping capacity assessment. Part I: an in vitro study on measurement reliability and a method of comparison in the determination of primary dental implant stability. *Clin Oral Implants Res* 2006;17(1):75-9.

- 6 Ersanli S, Karabuda C, Beck F, Leblebicioglu B. Resonance Frequency Analysis of One-Stage Dental Implant Stability During the Osseointegration Period. *J Periodontol* 2005; 76(7):1066-71.
- 7 Huang HM, Chiu CL, Yeh CY, Lin CT, Lin LH, Lee SY. Early detection of implant healing process using resonance frequency analysis. *Clin Oral Res* 2003; 14:437-43.
- 8 Lachmann S, Laval JY, Jäger B, Axmann D, Gómez-Román G, Groten M, Weber H. Resonance frequency analysis and damping capacity assessment. Part 2: peri-implant bone loss follow-up. An in vitro study with the Periotest and Osstell instruments. *Clin Oral Implants Res* 2006; 17(1):80-4.
- 9 Shiigai T. Pilot study in the identification of stability values for determining immediate and early loading of implants. *J Oral Implantol* 2007; 33(1):13-22.
- 10 Glauser R, Sennerby L, Meredith N, Reé A, Lundgren A, Gottlow J, Hämmerle CH. Resonance frequency analysis of implants subjected to immediate or early functional occlusal loading. Successful vs. failing implants. *Clin Oral Implants Res* 2004; 15(4):428-34.
- 11 Sennerby L, Meredith N. Implant stability measurements using resonance frequency analysis: biological and biomechanical aspects and clinical implications. *Periodontol* 2000. 2008; 47:51-66.
- 12 Atsumi M, Park SH, Wang HL. Methods Used to Assess Implant Stability: Current Status. *Int J Oral Maxillofac Implants* 2007; 22(5):743-54.
- 13 Buser D, Nydegger T, Hirt HP, Cochran DL, Nolte LP. Removal Torque Values of Titanium Implants in the Maxilla of Miniature Pigs. *Int J Oral Maxillofac Implants* 1998; 13 (5):611-9.
- 14 Cornelini R, Cangini F, Covani U, Barone A, Buser D. Immediate Restoration of Single-Tooth Implants in Mandibular Molar Sites: A 12-month Preliminary Report. *Int J Oral Maxillofac Implants* 2004; 19(6):855-60.
- 15 Brouwers JE, Lobbezoo F, Visscher CM, Wismeijer D, Naeije M. Reliability and validity of the instrumental assessment of implant stability in dry human mandibles. *J Oral Rehabil* 2009; 36(4):279-83.
- 16 Degidi M, Daprile G, Piattelli A. Determination of Primary Stability: A Comparison of the Surgeon's Perception and Objective Measurements. *Int J Oral Maxillofac Implants* 2010; 25:558-61.
- 17 Boronat-López A, Peñarrocha-Diago M, Martínez-Cortisoz O, Mínguez-Martínez I. Estudio del análisis de frecuencia de resonancia tras la colocación de 133 implantes dentales. *Med Oral Patol Oral Cir Bucal* 2006; 11:272-6.
- 18 Huwiler MA, Pjetursson BE, Bosshardt DD, Salvi GE, Lang NP. Resonance frequency analysis in relation to jawbone characteristics and during early healing of implant installation. *Clin Oral Implants Res* 2007; 18(3):275-80.
- 19 Bischof M, Nedir R, Sz mukler-Moncler S, Bernard JP, Samson J. Implant stability measurement of delayed and immediately loaded implants during healing. *Clin Oral Implants Res* 2004; 15(5):529-39.
- 20 Payam F, Andersson L, Sten G, Sharma O. Implant Stability, Tissue Conditions, and Patient Self-Evaluation after Treatment with Osseointegrated Implants in the Posterior Mandible. *Clin Implant Dent Relat Res* 2004; 6(1):24-32.
- 21 Balshi SF, Allen D, Wolfinger GJ, Balshi TJ. A Resonance Frequency Analysis Assessment of Maxillary and Mandibular Immediately Loaded Implants. *Int J Oral Maxillofac Implants* 2005; 20:584-94.
- 22 Brochu JF, Anderson JD, Zarb GA. The Influence of Early Loading on Bony Crest Height and Stability: A Pilot Study. *Int J Prosthodont* 2005; 18:506-12.
- 23 Calvo Guirado JL, Ortiz Ruíz J, Gómez Moreno G, López Marí L, Bravo González LA. Immediate loading and immediate restoration in 105 expanded-platform implants via the Diem System after a 16-month follow-up period. *Med Oral Patol Oral Cir Bucal* 2008; sep 1; 13 (9):576-81.

**CORRESPONDENCE**

N. Cervantes Haro  
 Instituto Mississippi  
 Departamento de Cirugía  
 Santísima Trinidad, 5  
 28010 Madrid

Contact e-mail: saraycalpe@gmail.com







**ZIACOM®**  
Making future together



Sede Central Europa | Europe Headquarters  
**Ziacom Medical SLU**  
Calle Bóhos, 2  
28320 Pinto - Madrid - ESPAÑA  
Tfno: +34 91 723 33 06  
[info@ziacom.es](mailto:info@ziacom.es) - [www.ziacom.es](http://www.ziacom.es)

Filiales | Subsidiaries  
**Ziacom Medical UK Ltd**  
London - UK  
Tel: +44 129 332 40 13  
[info@ziacom.co.uk](mailto:info@ziacom.co.uk) - [www.ziacom.co.uk](http://www.ziacom.co.uk)

Sede Central América | America Headquarters  
**Ziacom Medical USA LLC**  
333 S.E. 2nd Avenue, Suite 2000  
Miami, FL 33131 - USA  
Tel: +1 (786) 224 - 0089  
[info.usa@ziacom.es](mailto:info.usa@ziacom.es) - [www.ziacom.es](http://www.ziacom.es)

**Ziacom Medical Italy Srl**  
Milano - ITALIA  
Tel: +39 02 829 502 49  
[info@ziacom.it](mailto:info@ziacom.it) - [www.ziacom.it](http://www.ziacom.it)

**Ziacom Medical Portugal Lda**  
Lisboa - PORTUGAL  
Tel: +351 30 881 2641  
[info@ziacom.pt](mailto:info@ziacom.pt) - [www.ziacom.pt](http://www.ziacom.pt)

**Ziacom Medical France SAS**  
Toulouse - FRANCE  
Tél: +33 (0)182 88 04 33  
[info@ziacom.fr](mailto:info@ziacom.fr) - [www.ziacom.fr](http://www.ziacom.fr)

**Ziacom Medical Germany GmbH**  
Düsseldorf - DEUTSCHLAND  
Tel: +49 (0)308 96 77 89 91  
[info@ziacom.eu](mailto:info@ziacom.eu) - [www.ziacom.eu](http://www.ziacom.eu)

EN ENGLISH